

MICROBIOLOGY-ANATOMY

EXTRA-EDGE

Viral

Bact

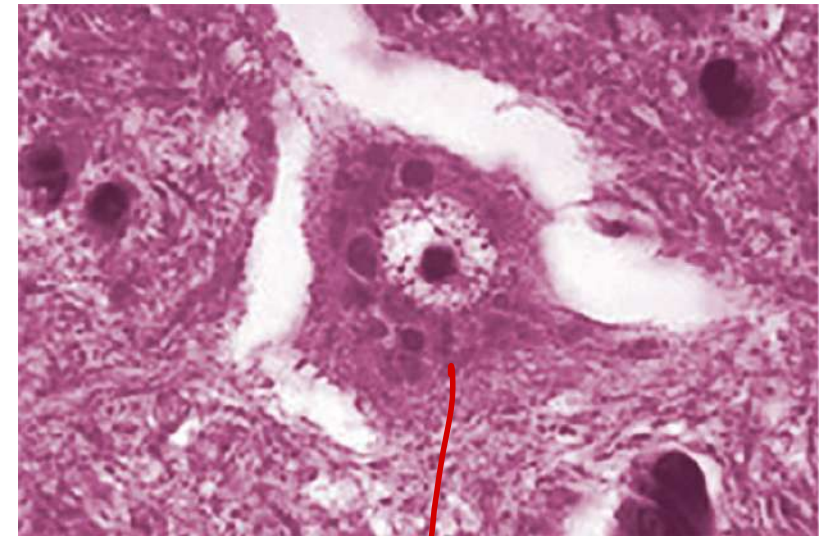
Parasito - Myco

Gen

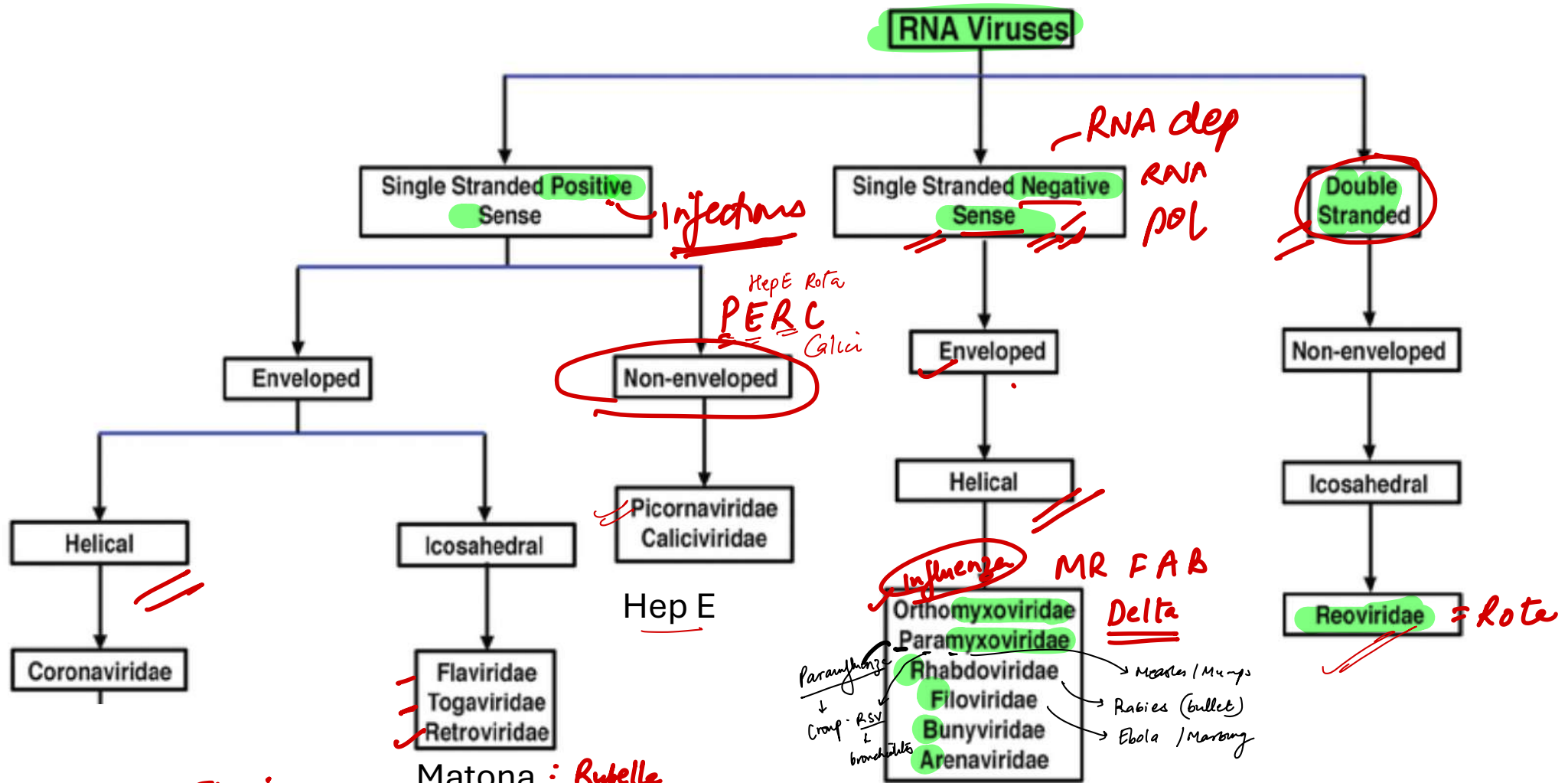
MICROBIOLOGY

19. A 25-year-old male presents with difficulty swallowing, hydrophobia, and aerophobia after being bitten by a bat. He develops spasms, agitation, and coma, eventually succumbing to respiratory failure. Histopathological examination of his brain is shown in the image. Which of the following best describes the viral genome of the pathogen?

- A. Double-stranded ~~DNA~~, enveloped
- B. Single-stranded RNA, positive-sense, enveloped
- C. ~~Single-stranded~~ RNA, negative-sense, enveloped
- D. Single-stranded RNA, segmented, non-enveloped



Rabies



Flavi:

HCV
 Yellow fever^a
 Dengue^a
 West Nile virus^a—meningoencephalitis, acute asymmetric flaccid paralysis
 Zika virus^a **JE, KFD**
 Toga **CREW**—Chikungunya virus^a (co-infection with dengue virus can occur), Rubella (formerly a togavirus), Eastern and Western equine encephalitis^a **Toga**

Picorna:

Poliovirus—polio-Salk/Sabin vaccines—IPV/OPV
 Echovirus—aseptic meningitis
 Rhinovirus—“common cold”
 Coxsackievirus—aseptic meningitis; herpangina (mouth blisters, fever); hand, foot, and mouth disease; myocarditis; pericarditis
 HAV—acute viral hepatitis **PERCH**

Arca:

LCMV—lymphocytic choriomeningitis virus
 Lassa fever encephalitis—spread by rodents

Bunya:

California encephalitis^a
 Sandfly/Rift Valley fevers^a **Chandipura**
 Crimean-Congo hemorrhagic fever^a **Kala**
 Hantavirus—hemorrhagic fever, pneumonia **Oraya**

18. There is an outbreak of hepatitis A infection in a college hostel. Which of the following is false about this infection?

- A. It does not cause hepatocellular carcinoma
- B. The incubation period is 2-6 weeks
- ~~C.~~ Caused by an enveloped ssRNA virus
- D. Case fatality rate is 0.1%

A — feco-oral
E —

Hep A → Picorna nonenv

B → DNA enveloped

C → Flavi

D → -ve strand env

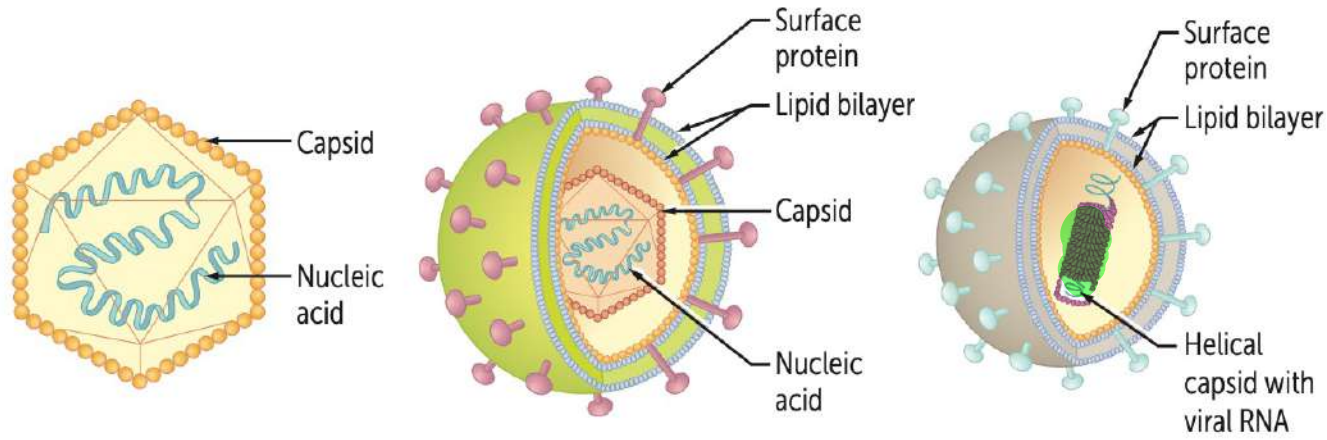
E → PERC nonenv

15. Identify morphology of coronavirus

- A. ~~Naked~~ helically symmetrical viruses
- B. Enveloped icosahedrally symmetrical viruses
- C. ~~Enveloped~~ helically symmetrical viruses
- D. Variably ~~enveloped~~ viruses with a complex symmetry

PERC
=

enveloped



Naked (nonenveloped) virus with icosahedral capsid

Polio
Hep A

Enveloped virus with icosahedral capsid

YF
Rubella

Enveloped virus with helical capsid

All other RNA

MR FAB
- Cornea

Flavi
- Toga
- Retio
- Reo

DNA - icosahedral
Helical: Tobacco mosaic
except

Complex → Pox

186. A 30-year-old male presents to the emergency department with sudden-onset chest pain, fever, and significant intercostal muscle tenderness. He works in agriculture, and his symptoms started after eating street food. Upon examination, he shows signs of pleuritic chest pain and muscle stiffness. He reports a recent fever and generalized muscle aches. He also has a past medical history of diabetes. Given the context and clinical presentation, which of the following pathogens is most likely responsible for his condition?

A. Group A Coxsackievirus

B. Group B Coxsackievirus

C. Enterovirus

D. Human Herpesvirus 6 (HHV-6)

Group A Coxsackieviruses

1. Aseptic meningitis (A7, A9)
2. Herpangina (vesicular Pharyngitis)
3. Hand foot and mouth disease (also by Enterovirus:71)
4. Acute hemorrhagic conjunctivitis-Caused by Coxsackie-A24 and Enterovirus 70

Group B Coxsackieviruses

1. Aseptic meningitis (B1-6)
2. Pleurodynia (Epidemic myalgia or Bornholm disease)
3. Myocarditis, pericarditis
4. Hepatitis and Pneumonia
5. Pancreatitis leading to Juvenile Diabetes mellitus - Coxsackie B4

25. A 6-month-old infant is brought to the emergency department with difficulty swallowing, a weak cry, and generalized weakness. The child's mother reports that the infant consumed honey several days ago. On examination, the infant is floppy, with a weak cry and poor muscle tone. The diagnosis of infant botulism is made. Which of the following adenovirus serotypes is most commonly associated with diarrhea in infants and would be a potential differential diagnosis for this case?

~~A. 40, 41~~

B. 8, 19, 37

C. 1, 2, 3, 5

D. 3, 7, 14

TABLE 58-2

Diseases associated with various serotypes of adenoviruses

Disease	Serotypes
Acute respiratory disease	4, 7, 14, 21
Acute febrile pharyngitis	
Endemic	1, 2, 5, 6
Epidemic	3, 4, 7
Pneumonia	1-3, 7
Pharyngoconjunctival fever	3, 4, 7
Acute follicular conjunctivitis	3, 4, 11
Epidemic keratoconjunctivitis	19, 37
Gastroenteritis and diarrhea	40, 41
Intussusception	1, 2, 5
Acute hemorrhagic cystitis	11, 21
Disseminated infection	5, 34, 35, 43-47

$3 + 4 = 7 \neq 11$

64. Which of the following is not a continuous cell line used for viral culture?

A. Vero

B. Hep2

C. WI-38

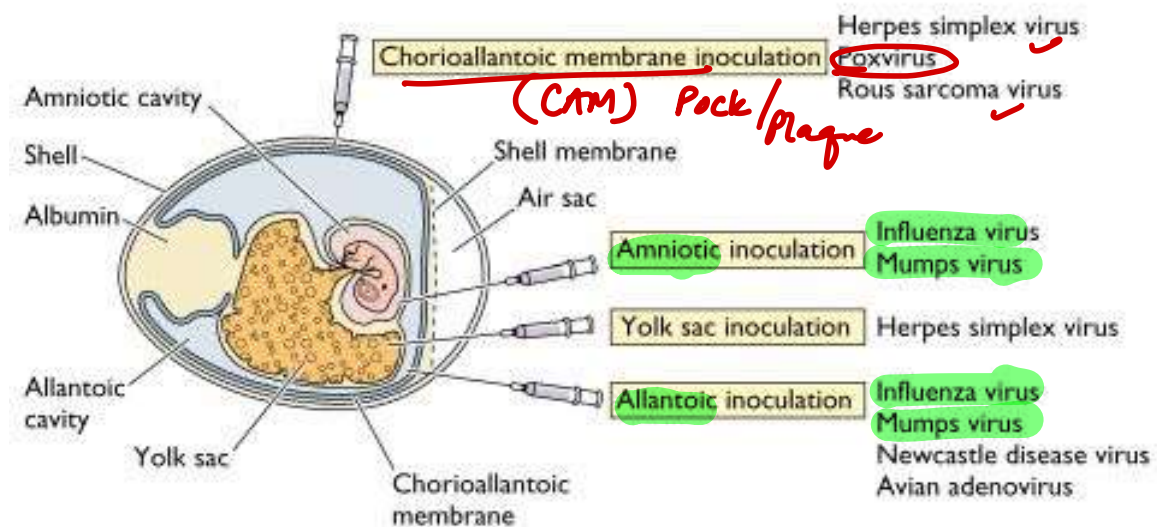
D. Hela

TABLE 53-3

Cell lines in common use

Cell lines	Examples
Primary cell culture	Rhesus monkey kidney cell culture Human amnion cell culture Chick embryo fibroblast cell culture
Diploid cell strains	Human embryonic lung cell strain (WI-38) Rhesus embryo cell strain (HL-8)
Continuous cell lines	Human carcinoma of cervix cell line (HeLa) Human epithelioma of larynx cell line (Hep-2) Human carcinoma of nasopharynx cell line (KB) Human synovial carcinoma cell line (McCoy) Sternal marrow cell line (Detroit-6) Human conjunctiva (C), intestine (I), liver (L), and kidney (K) cell line (Chang C/I/L/K) Vervet monkey cell line Baby hamster kidney cell line (Vero)

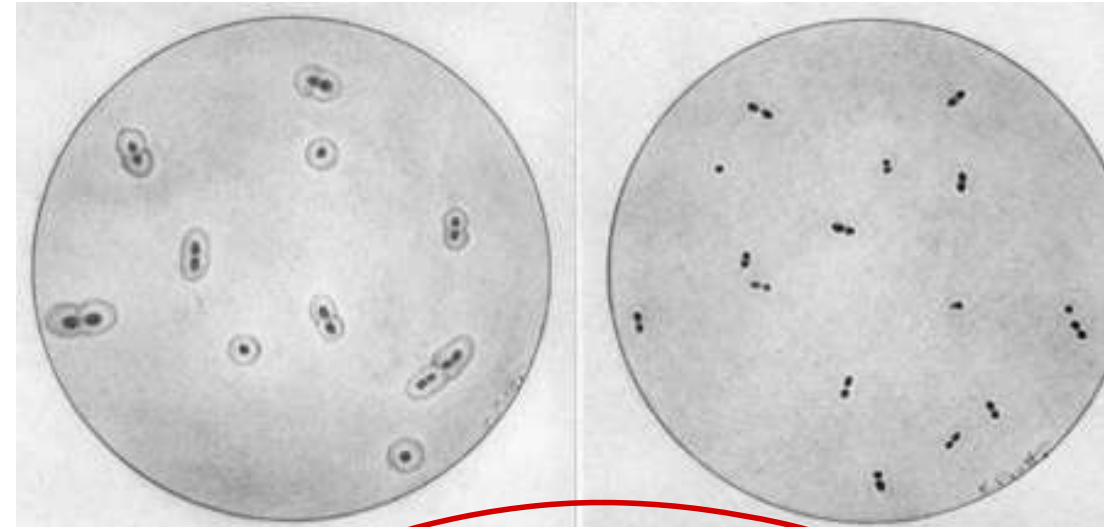
Animal inoculation / Suckling mice → *Coxsackie.*



Human fibroblast + CMV

1. The following phenomenon not be observed in?

- A. Bacillus anthracis
- B. Klebsiella pneumoniae
- ~~C.~~ Neisseria gonorrhoeae
- D. Hemophilus influenzae



SHiN

Quellung xn

Polysachharide capsule: + VACCINE = *S. pneumoniae* / Hib / *N. meningitidis* / Vi typhoid
Grp B Strep, E.coli, Klebsiella, Pseudomonas, Salmonella

B. Pertussis //

C. Perfringens //

Cryptococcus - India Ink (Negros)

Hyaluronic acid: *S. pyogenes*

Polypeptide: *B. anthracis*

F1 protein: *Y. pestis*

In vivo biofilm-producing bacteria

S. epidermidis

Viridans streptococci (*S. mutans*, *S. sanguinis*)

P. aeruginosa

Nontypeable (unencapsulated) *H. influenzae*

Hib x x

Catheter and prosthetic device infections

Dental plaques, infective endocarditis

Respiratory tree colonization in patients with cystic fibrosis, ventilator-associated pneumonia

Contact lens-associated keratitis

Otitis media

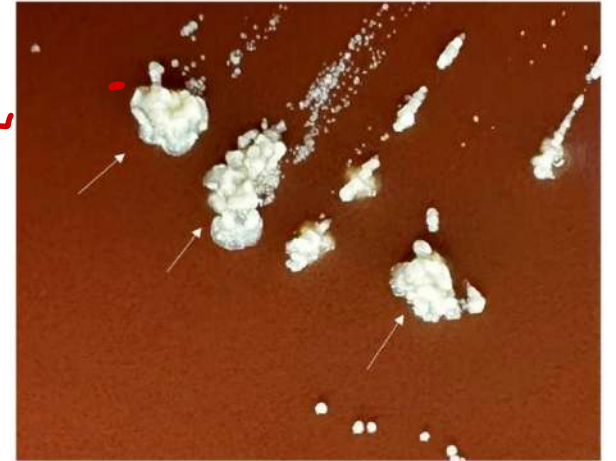↓ metabolism

Ab resistance

183. A 34-year-old male presents with a fluctuant mass in the jaw region and purulent discharge from multiple sinuses. The culture shows the colonies displayed in the given image below. Which of the following is a key feature of the causative organism?

- A. Gram-negative obligate anaerobe
- B. Gram-positive facultative anaerobe
- C. Gram-positive obligate anaerobe**
- D. Acid-fast bacterium

Azelenomyces



Obligate anaerobes

Actinomyces
Bacteroides
Clostridium
Fusobacterium

Peptostreptococcus
(aero-tolerant)

Lack catalase / SOD

Ineffective: Ag (microreading)

Facultative anaerobes

Staphylococcus
Streptococcus
Enterobacteraceae
Hemophilus
Vibrio ✓✓

Microaerophilic (2-10%)

• Helicobacter
• Campylobacter
• M. bovis

Obligate intracellular

Rickettsia, Chlamydia, Coxiella
Rely on host ATP

Stay inside (cells) when it is Really Chilly and Cold

Facultative intracellular

Salmonella, Neisseria, Brucella, Mycobacterium,
Listeria, Francisella, Legionella, Yersinia pestis

Some Nasty Bugs May Live FacultativeLY

12. Identify the microaerophilic bacteria from the list:

1. Positive CLO test. *H. pylori*
2. Gram-negative bacilli implicated in GBS *Campy*
3. Gram-negative curved bacilli with 'fish-in-stream' appearance
4. Bacteria showing 'mercury drop' colonies.
5. LJ medium showing ruff, buff, tough colonies.

A. 2 and 5

B. 3 and 4

C. 1 and 4

D. 1 and 2

M. Tb

B. pertussis

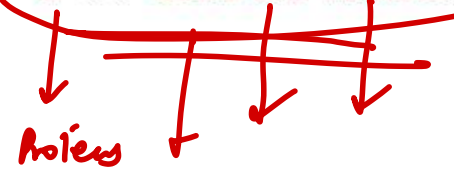
Vibrio

Urease-positive organisms

Proteus, *Cryptococcus*, *H pylori*, *Ureaplasma*,
Nocardia, *Klebsiella*, *S epidermidis*, *CONS*,
S saprophyticus. Urease hydrolyzes urea
to release ammonia and $\text{CO}_2 \rightarrow \uparrow \text{pH}$.
Predisposes to struvite (magnesium
ammonium phosphate) stones, particularly
Proteus.

Trachopyton

Pee CHUNKSS.



3. Identify the staining method for a tissue biopsy of the painless ulcer shown below:

A. Fontana's method

~~B. Levaditi's method~~

C. Castaneda's method

D. Albert's method

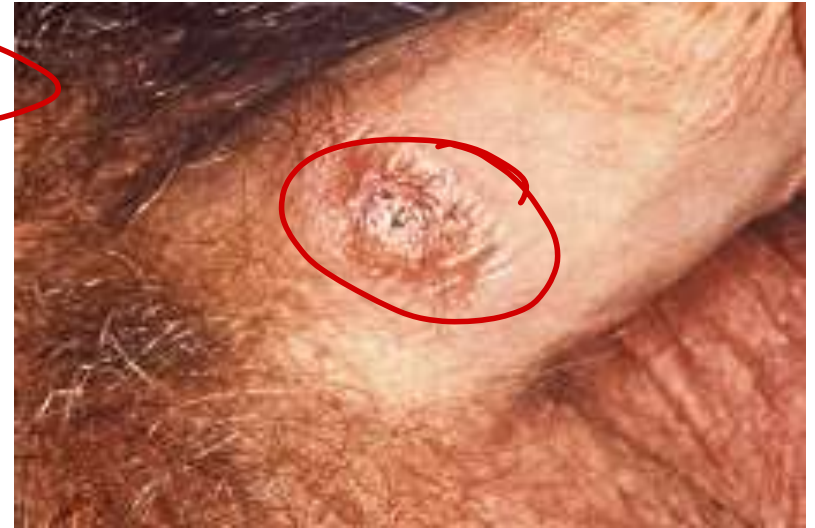Diphtheria

fluid
Smear

Silver Impregnation

tissue

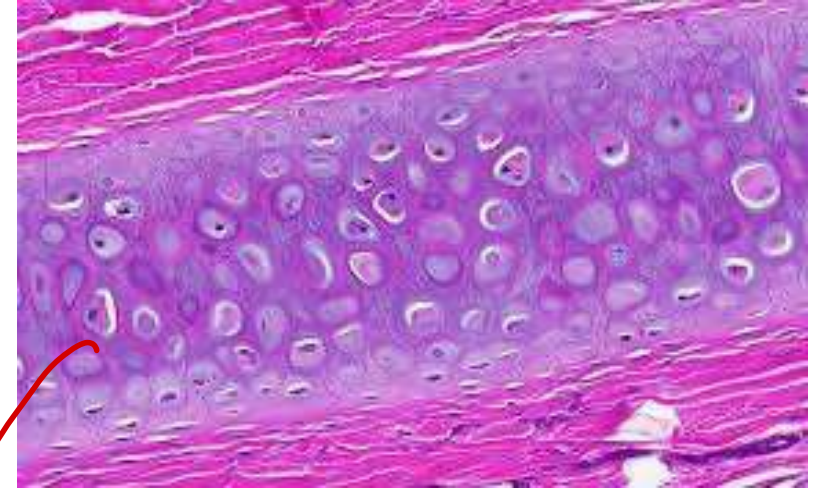
Brucella



2. Which of the following stains are used to visualize the specific fibers present in the following cartilage?

- A. Bielchowsky stain *neurons*
- B. Verhoeff's stain**
- C. GMS Silver stain *- fungi / PCP*
- D. Alcian Blue stain

acetic mucin
Barrett



elastic cartilage

9. Which of the following is a pigment-producing species of mycobacteria?

A. M. ulcerans

B. M. scrofulaceum

C. M. avium intracellulare complex

D. M. xenopi

Runyon Classification

- **Group 1: Photochromogens** *MSK*
Mycobacterium kansasii, *Mycobacterium marinum*,
Mycobacterium simiae
- **Group 2: Scotochromogens** *rare* *God save dat*
Mycobacterium scrofulaceum, *Mycobacterium szulgai*,
Mycobacterium gordonae
- **Group 3: Nonphotochromogens** *x pigms*
Mycobacterium avium-intracellulare, *Mycobacterium malmoense*,
Mycobacterium xenopi
- **Group 4: Fast growers** *x pigms*
Mycobacterium fortuitum, *Mycobacterium chelonae*,
Mycobacterium abscessus

TABLE 42-1

Human infections caused by atypical *Mycobacterium* species

Bacteria	Diseases
<i>Mycobacterium kansasii</i>	Pulmonary disease
<i>Mycobacterium marinum</i>	Swimming pool granuloma
<i>Mycobacterium simiae</i>	Pulmonary disease (rare)
<i>Mycobacterium scrofulaceum</i>	Lymphadenopathy
<i>Mycobacterium gordonae</i>	Pulmonary disease (rare)
<i>Mycobacterium szulgai</i>	Pulmonary disease and bursitis (occasional)
<i>Mycobacterium xenopi</i>	Chronic pulmonary disease
<i>Mycobacterium avium</i> complex	Pulmonary disease, lymphadenopathy, and disseminated disease
<i>Mycobacterium ulcerans</i>	Buruli ulcer
<i>Mycobacterium fortuitum</i>	Post-trauma chronic abscesses
<i>Mycobacterium chelonae</i>	Post-trauma chronic abscesses
<i>Mycobacterium abscessus</i>	Abscesses
<i>Mycobacterium goodii</i>	Disseminated diseases (AIDS-related)

13. Which of the following is not a characteristic feature of El Tor vibrio?

- ~~A. Resistant to El Tor phage V~~
- B. Intrinsic resistance to polymyxin B ✓
- C. Voges-Proskauer test is positive ✓
- D. Not susceptible to group IV phage ✓

TABLE 35-2

Vibrio cholerae biotypes

Properties	<i>Vibrio cholerae</i> biotype	
	Classical	Eltor
Hemolysis of sheep RBCs	-	+
Agglutination of chick erythrocytes	-	+
Voges-Proskauer test	-	+
<u>Polymixin B sensitivity</u>	+	-
Susceptibility to		
<u>Mukerjee Group IV Phage</u>	+	-
<u>Eltor phage 5</u>	-	+
<u>Vibriostatic (O/129) agent</u>	+	-

17. A 34-year-old man presents with a discharging wound post-operatively. Cultures reveal infection with MRSA. Which of the following is the gene implicated?

A. MecA

B. MecB

C. MecC

D. MecM

chromosomal coded

PBP → PBP 2a



penicillinase → plasmid encoded

URSA - plasmid encoded

DatA → Dlac

'jumping gene'

transposon

MRSA (methicillin-resistant *S aureus*) —
important cause of serious healthcare-associated and community-acquired infections. Resistance due to altered penicillin-binding proteins (conferred by *mecA* gene). Some strains release Pantone-Valentine leukocidin (PVL), which kills leukocytes and causes tissue necrosis.

14. Which of the following microbes is also referred to as Friedlander's bacillus?

A. Klebsiella pneumoniae

B. Corynebacterium diphtheria → Klebs Loeffler

C. Chlamydia trachomatis

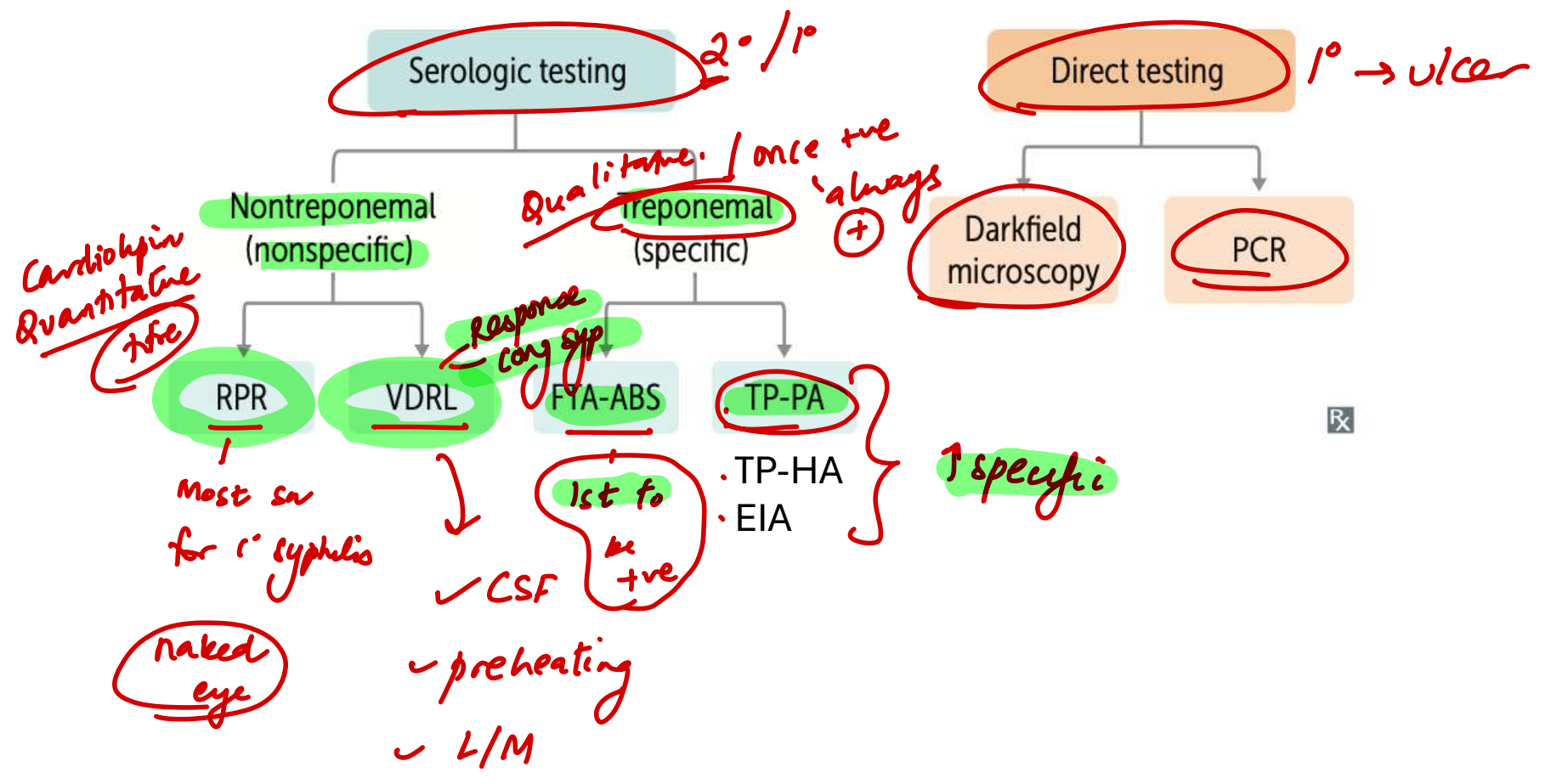
D. Mycoplasma pneumoniae → Eaton agent

E. H.aegypticus - conjunctivitis → Koch week

F. H.influenzae
→ Pfeiffer

16. Which of the following is a false statement regarding the serological tests of syphilis?

- A. Rapid plasma reagin test is a group specific treponemal test
- B. VDRL test is the test of choice for response to therapy
- C. VDRL is the test of choice for examining CSF
- D. Treponemal tests are likely to remain reactive even after adequate therapy



122. A throat swab taken from a patient who presented with fever, dysphagia and cervical lymphadenopathy was sent for culture on potassium tellurite agar. The resultant colonies had a poached egg appearance. Which among the following is the most likely organism implicated here?

A. *Corynebacterium diphtheriae gravis*

~~B. *Corynebacterium diphtheriae mitis*~~

C. *Corynebacterium diphtheriae intermedius*

D. *Corynebacterium pseudotuberculosis*

TABLE 27-2

Salient features of various biotypes of *Corynebacterium diphtheriae*

Features	Gravis	Intermedius	Mitis
Size	Short rods	Long rods	Long curved rods
Pleomorphism	+	+++	++++
Granules	Few or no	Few	Prominent
Staining reaction	Uniform	Irregular	Irregular
Colony	Daisy head	Frog's egg	Poached egg
On tellurite agar			
Surface	Matt	Shining	Glossy
Consistency	Brittle	Weak buttery	Buttery
Hemolysis	Variable	Nonhemolytic	Hemolytic
Starch fermentation	+	-	+
Phage types	14	3	4
Toxigenicity of strains	95%	99%	85%
Antigenic types	13	4	40
In broth medium	Pellicle formation and granular deposits	No pellicle, Granular deposit	Diffuse turbidity

Chlamydiae cannot make their own ATP. They are obligate intracellular organisms that cause mucosal infections. 2 forms:

- **Elementary body** (small, dense) is “infectious” and enters cell via endocytosis; transforms into reticulate body.
- **Reticulate body** replicates in cell by fission; reorganizes into elementary bodies.

Chlamydia trachomatis causes neonatal and follicular adult conjunctivitis **A**, nongonococcal urethritis, PID, and reactive arthritis.

Chlamydophila pneumoniae and *Chlamydophila psittaci* cause atypical pneumonia; transmitted by aerosol.

Chlamydial cell wall lacks classic peptidoglycan (due to reduced muramic acid), rendering β -lactam antibiotics ineffective.

Chlamys = cloak (intracellular).

C psittaci—has an avian reservoir (parrots), causes atypical pneumonia.

Lab diagnosis: PCR, NAAT. Cytoplasmic inclusions (reticulate bodies) seen on Giemsa or fluorescent antibody–stained smear.

Treatment: doxycycline, azithromycin (for pregnant patients). Add ceftriaxone if concurrent gonorrhea testing is positive.

Chlamydia trachomatis serotypes

Types A, B, and C

Chronic infection, cause blindness due to follicular conjunctivitis in resource-limited areas.

ABC = Africa, Blindness, Chronic infection.

Types D–K

Urethritis/PID, ectopic pregnancy, neonatal pneumonia (staccato cough) with eosinophilia, **neonatal conjunctivitis** (1–2 weeks after birth).

D–K = everything else.

Neonatal disease can be acquired during vaginal birth if pregnant patient is infected.

Types L1, L2, and L3

lymphogranuloma venereum—small, painless ulcers on genitals → swollen, painful inguinal lymph nodes that ulcerate (buboes). Treat with doxycycline.

	<u>Salmonella typhi (ty-Vi)</u>	<u>Salmonella spp. except S typhi</u>	<u>Shigella</u>
RESERVOIRS	Humans only	Humans and animals	Humans only
SPREAD	Hematogenous spread	Hematogenous spread is rare	Cell to cell; no hematogenous spread
H ₂ S PRODUCTION	Yes	Yes	No
<u>FLAGELLA</u>	Yes (<u>salmon swim</u>)	Yes (<u>salmon swim</u>)	No
VIRULENCE FACTORS	Endotoxin; Vi capsule (pronounce "tyVi")	Endotoxin	Endotoxin; Shiga toxin (enterotoxin)
INFECTIOUS DOSE (ID ₅₀)	High—large inoculum required; acid-labile (inactivated by gastric acids)	High	Low—very small inoculum required; acid stable (resistant to gastric acids)
EFFECT OF ANTIBIOTICS ON FECAL EXCRETION	Prolongs duration	Prolongs duration	Shortens duration (shortens <i>Shigella</i>)
IMMUNE RESPONSE	Primarily monocytes	PMNs in disseminated disease	Primarily PMN infiltration
GI MANIFESTATIONS	Constipation, followed by diarrhea	Diarrhea (possibly bloody)	Crampy abdominal pain → tenesmus, bloody mucoid stools (bacillary dysentery)
VACCINE	Oral vaccine contains live attenuated <i>S typhi</i> IM vaccine contains Vi capsular polysaccharide	No vaccine	No vaccine
UNIQUE PROPERTIES	Causes typhoid fever (salmon-colored truncal macular rash, abdominal pain, fever [pulse-temperature dissociation]; later GI ulceration and hemorrhage); treat with ceftriaxone or fluoroquinolone Carrier state with gallbladder colonization	Poultry, eggs, pets, and turtles are common sources Treatment is supportive; antibiotics are not indicated in immunocompetent individuals	4 F's: fingers, flies, food, feces In order of decreasing severity (less toxin produced): <i>S dysenteriae</i> , <i>S flexneri</i> , <i>S boydii</i> , <i>S sonnei</i> Invasion of M cells is key to pathogenicity; infectious dose is low

Salmonella
↓
Wilson Blair

Acid labile:
V.cholera, Rhinovirus

10. A 25-year-old HIV/AIDS man presents with fever, headache, photophobia and neck rigidity since the last 2 days. What is the empirical therapy of choice for this patient?

- A. Cefepime + Vancomycin + Ampicillin - extremes ages / immunocompr.
GP
- B. Ceftriaxone + Vancomycin
- C. Isoniazid + Rifampicin + Pyrazinamide + Ethambutol → TB
- D. Liposomal amphotericin B + Fluorocytosine → cryptococcus - HIV/AIDS

Common causes of meningitis

NEWBORN (0-6 MO)	CHILDREN (6 MO-6 YR)	6-60 YR	60 YR +
Group B <i>Streptococcus</i>	<i>S pneumoniae</i>	<i>S pneumoniae</i>	<i>S pneumoniae</i>
<i>E coli</i>	<i>N meningitidis</i>	<i>N meningitidis</i>	<i>N meningitidis</i>
<i>Listeria</i>	<i>H influenzae</i> type b	Enteroviruses	<i>H influenzae</i> type b
	Group B <i>Streptococcus</i>	HSV	Group B <i>Streptococcus</i>
	Enteroviruses		<i>Listeria</i>

Give ceftriaxone and vancomycin empirically (add ampicillin if *Listeria* is suspected; add acyclovir if viral encephalitis is suspected).

Viral causes of meningitis: enteroviruses (especially coxsackievirus), HSV-2 (HSV-1 = encephalitis), HIV, West Nile virus (also causes encephalitis), VZV.

MCC

20. Which among the following is not a sexual spore?

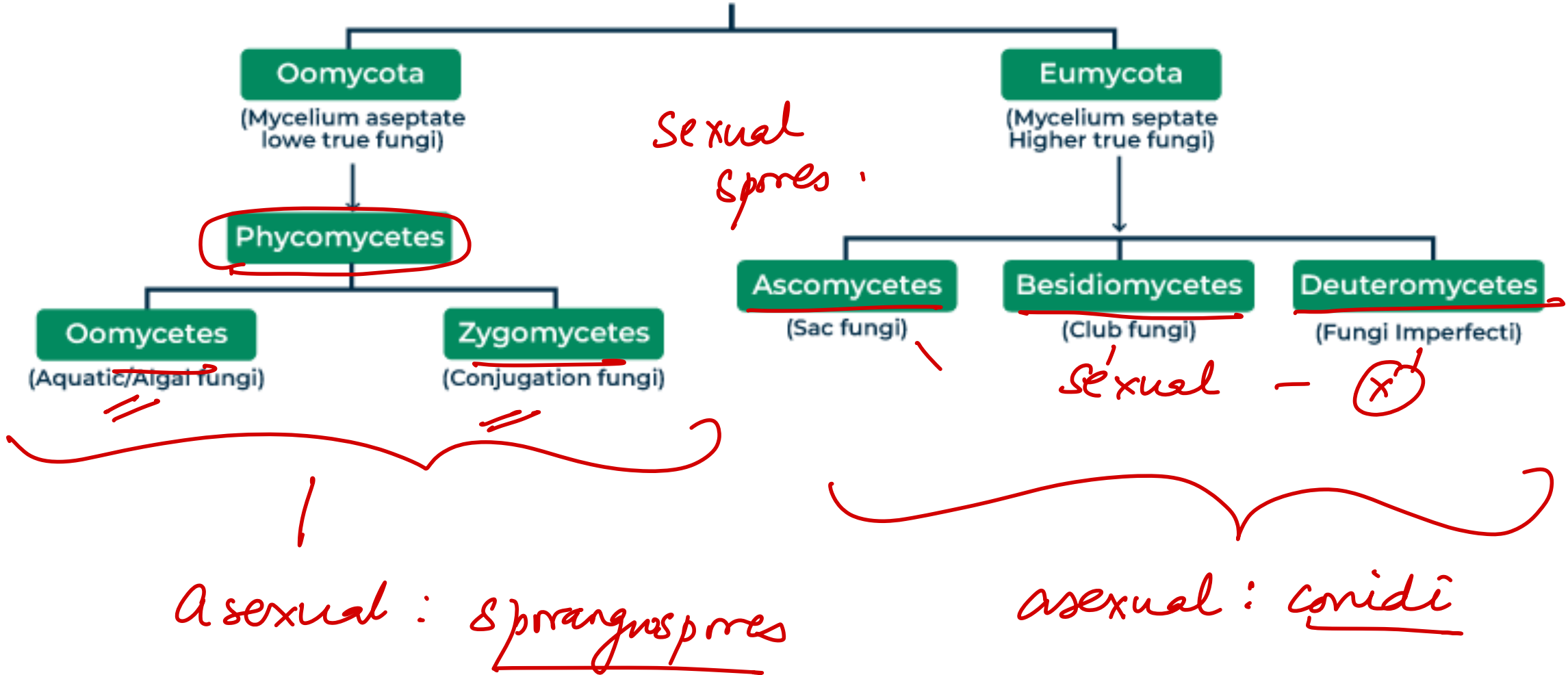
A. Zygosporangium

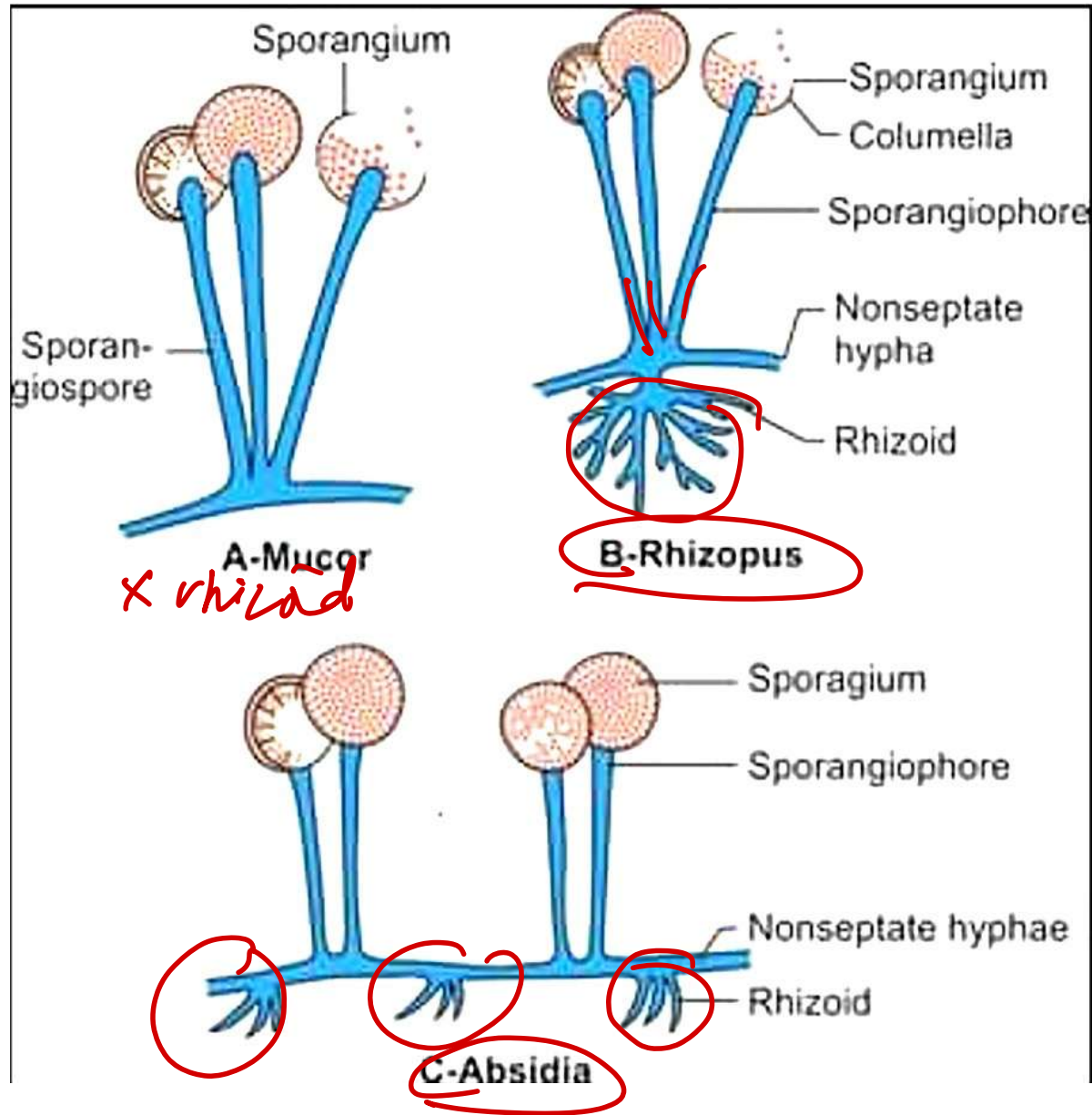
B. Sporangium

C. Basidiospore

D. Ascospore

Kingdom Fungi





Nematode routes of infection

Ingested—Enterobius, Ascaris, Toxocara,
Trichinella, Trichuris

Cutaneous—Strongyloides, Ancylostoma,
Necator Hookworm] → C2M

Bites—Loa loa, Onchocerca volvulus,
Wuchereria bancrofti

filaine

Schistosoma

21. A 22-year-old man comes with complaints of intermittent bloody diarrhea for 3 weeks after consuming street food during his travel. He is febrile and has RUQ tenderness. Which of the following is the infective form of the likely protozoan causing this disease?

A. Trophozoite → trichomonas / Acanthamoeba / Naegleria.

B. Mature quadrinucleate cyst → E. histolytica / Giardiasis

C. Metacyclic trophozoite

D. Oocyst

E. Cyst → B. coli

F. Sporozoite - Plasmodium

G. Promastigote

L. donovani

→ Trypanosome

Toxo → Cyrtocyclops / Isospora

⊗ immed inf w 5d immed inf //

Q.P
inf

22. Which of the following refers to a host in which the larval stage of the parasite remains viable without further development?

- A. Definitive host → sexual
- B. Intermediate host → asexual
- C. Paratenic host → harbors larva
- D. Reservoir host → harbors parasite adult

DH Not man

Malaria

Babesia

Toxoplasma

E. Granulosus

DH
Anopheles
Hard tick
Cat
Dog

TOXIN	SOURCE	ACTION	SYMPTOMS	TREATMENT
Histamine (scombroid poisoning)	Spoiled dark-meat fish such as <u>tuna</u> , <u>mahi-mahi</u> , <u>mackerel</u> , and <u>bonito</u>	Bacterial <u>histidine decarboxylase</u> converts <u>histidine</u> to <u>histamine</u> Frequently <u>misdiagnosed as fish allergy</u>	Mimics anaphylaxis: oral burning sensation, facial flushing, erythema, urticaria, itching; may progress to bronchospasm, angioedema, hypotension	<u>Antihistamines</u> Albuterol +/- epinephrine
Tetrodotoxin	<u>Pufferfish</u>	Binds fast voltage-gated <u>Na⁺ channels</u> in nerve tissue, preventing depolarization	Nausea, diarrhea, paresthesias, weakness, dizziness, loss of reflexes <u>LA</u>	Supportive
<u>Ciguatoxin</u>	Reef fish such as barracuda, snapper, and moray eel	Opens <u>Na⁺ channels</u> , causing depolarization	Nausea, vomiting, diarrhea; perioral numbness; reversal of hot and cold sensations; bradycardia, heart block, hypotension	Supportive

GN / Pseudomonas

33. Which of the following tests is a type of ring precipitation test?

A. VDRL test

B. Rose Bengal test

C. Ascoli's thermoprecipitation test

D. Elek test

PRECIPITATION/FLOCCULATION: Soluble Ag
Ring test: Ascoli → Anthrax Lancefield → CAg of B. cereus
✓ Slide: VDRL] syphilis
✓ Tube: Kahn]
Immunodiffusion/ Gel: Elek test
Rocket electrophoresis

AGGLUTINATION → Insoluble Ag
Slide: Blood grouping Rose Bengal : Brucella
Tube: Widal Weil Felix Paul-Bunnell CAT SAT MAT
0/4 > 1:80 acute EBV EBV Mycop + Brucella ↓ Leptospira
Coombs test
DCT : AIHA ICT : Rh iso
Indirect/Passive agglutination:
Latex-ASO, CRP, RF, HCG
Heme-Rose Waaler test → RF

Complement fixation:
Wassermann, TPI
Sabin Feldman

5. What is the temperature used for this method of sterilisation?

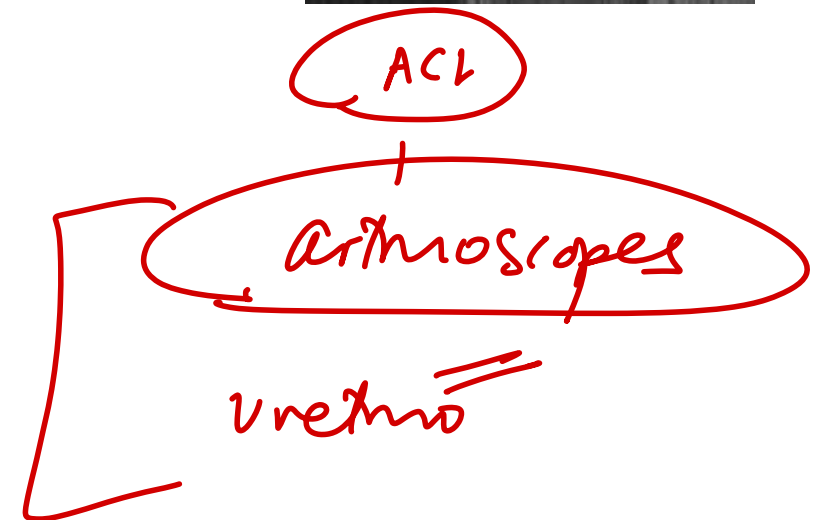
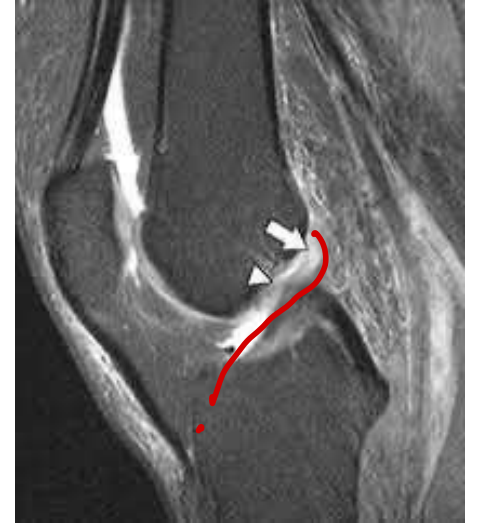- ✓ A. 121°C for 15 minutes
- B. 140°C for 120 minutes
- C. 50°C for 120 minutes → ETO
- D. 160°C for 120 minutes → Hot Air Oven.



4. Which of the following will be used to sterilise the instrument used to treat the following injury?

- A. Ethylene oxide
- B. Gamma rays
- C. Hydrogen peroxide
- D. Ultraviolet rays

Plasma sterilis^o



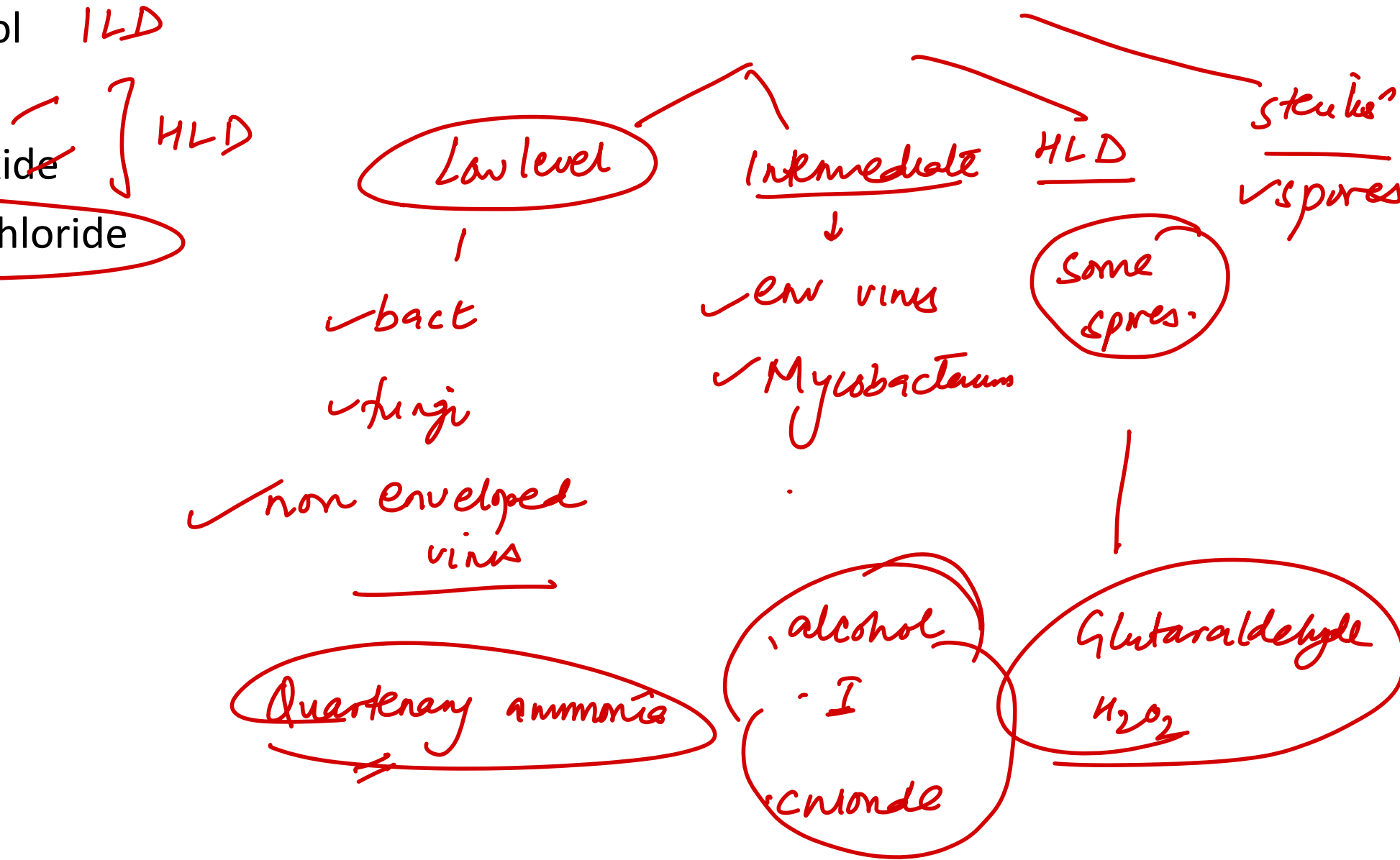
6. Which among the following is a low-level disinfectant?

A. Isopropyl alcohol *LLD*

B. Glutaraldehyde

C. Hydrogen peroxide

D. Benzalkonium chloride



2. Which of the following method of disinfection and sterilization can also kill spores?

- 1. Glutaraldehyde ✓
 - 2. Ethylene oxide ✓
 - 3. Pasteurization ✗✗
 - 4. Orthophthalaldehyde ✓
-

A. 1, 3 and 4

~~B. 1, 2 and 4~~

C. 2, 3 and 4

~~D. 1, 2, 3 and 4~~

Disinfectant	Activity	Advantages	Disadvantages	Recommendation
Glutaraldehyde	Broad spectrum microbicidal and sporicidal	Good compatibility	Requires activation Produces irritant fumes	For fibroscope and respiratory equipment
Orthophthaldehyde	Broad spectrum microbicidal and sporicidal	No activation required No fumes	Costly Stains equipment	For scopes Alternative to glutaraldehyde
<u>Iodine compounds</u>	Microbicidal spares M Tuberculosis and spores	Rapid action	Corrosive to metals, plastic and rubber Stains items	As an antiseptic
<u>Alcohols</u>	Wide microbicidal activity Non sporicidal	Non staining	Flammable	Hand disinfection For endoscopes
<u>Phenols</u> <i>RWC</i>	Wide microbicidal activity Non sporicidal	Easily available Low cost	Irritant to skin Depigmentation	As surface disinfectant
<u>Quaternary Ammonium compounds</u>	Microbicidal spares M Tuberculosis, Not sporicidal, Not virucidal	Less irritant Good detergent property	Occupational asthma	As surface disinfectant For non-critical items
Peracetic acid	Broad spectrum microbicidal and sporicidal	No activation required Wide compatibility	Expensive Irritant to eye and skin	For fibrosopes
<u>Chlorines</u>	Wide microbicidal activity Non sporicidal	Low cost Fast acting	Corrosive to metals	Surface disinfectant To clean blood and body fluid spills
Hydrogen Peroxide	Broad spectrum microbicidal and sporicidal	No activation required	Serious eye damage Incompatible with some metals	Fogging of operating room For endoscopes
Formaldehyde	High level disinfectant	Non corrosive	Pungent odor and irritant fumes Carcinogenic	Withdrawn from use

ANATOMY

31. Arrange the following events of pre-embryonic development in order, from the earlier stage to the later stage:

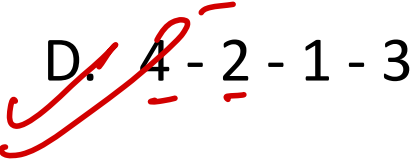
- 1. Cavitation**
 - 2. Compaction**
 - 3. Implantation**
 - 4. Cleavage**
- 

A. ~~2 - 4 - 1 - 3~~

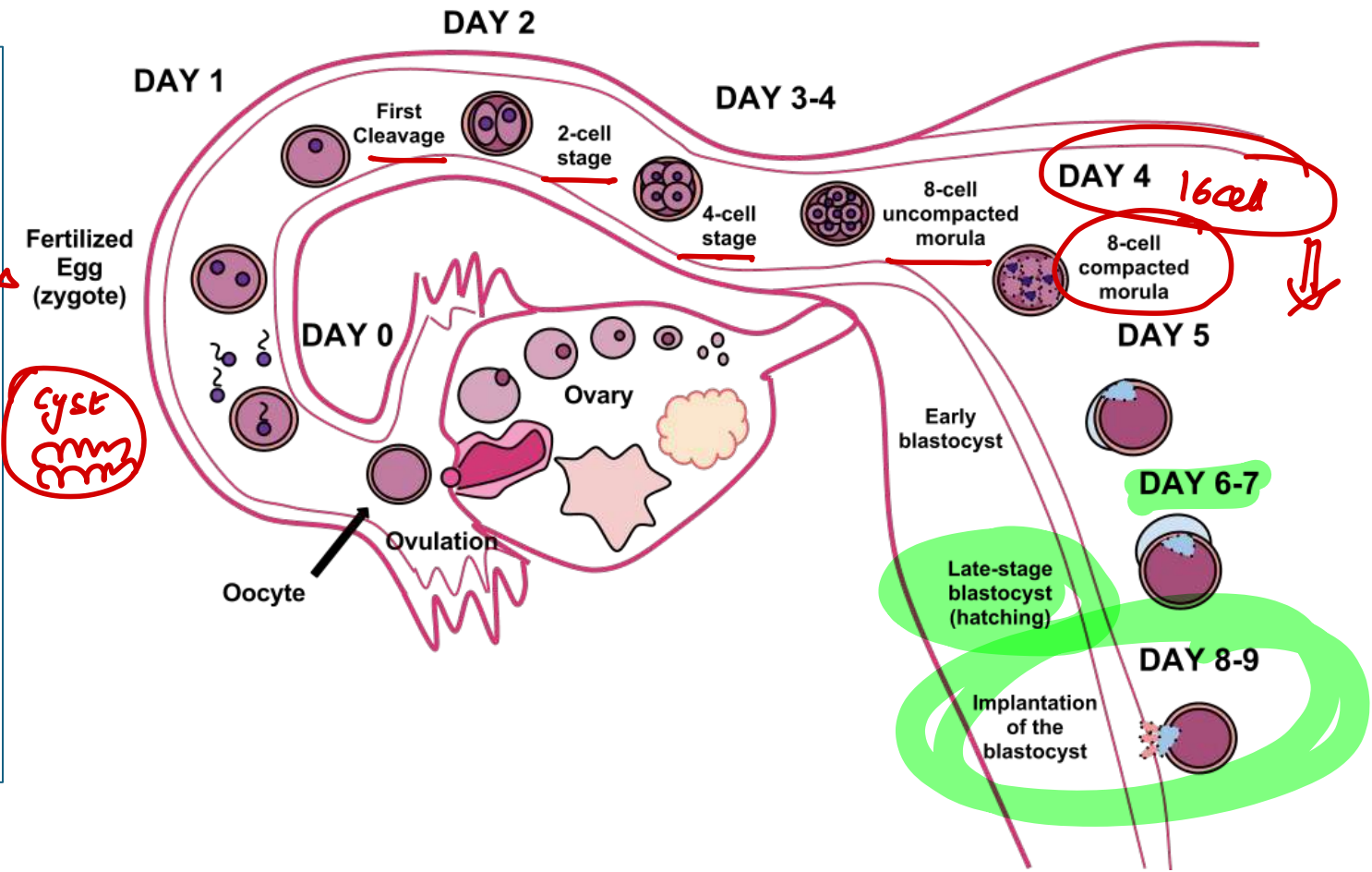
B. ~~3 - 1 - 2 - 4~~

C. 4 - 2 - 3 - 1


D. 4 - 2 - 1 - 3



- **Fertilisation**
- Cleavage → blastomere - 8 cell
- Compaction
- **Differentiation** 8 cell - 16 cell (morula) *- extra*
- Cavitation - blastocyst
- Hatching - ZP separates
- Implantation 6-9d
- Bilaminar *(epi/hypo) → 9d*
- **Gastrulation** - 12d



migrate $\begin{matrix} \text{====} & \text{ecto} \\ \text{====} & \text{meso} \\ \text{====} & \text{endoderm 1st} \end{matrix}$



33. The membranous labyrinth develops from which structure?

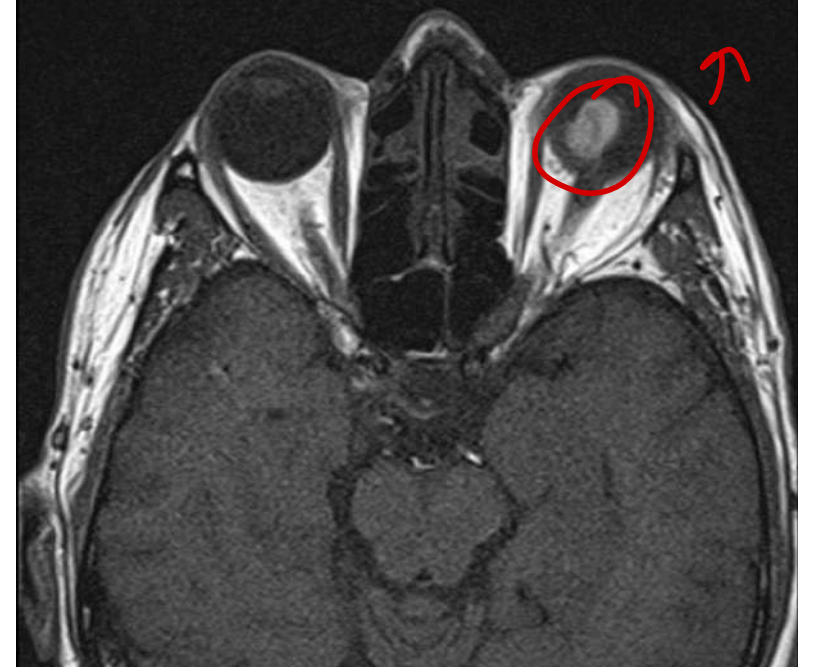
- A. First pharyngeal pouch
- B. First pharyngeal cleft
- ~~C. Otic vesicle~~
- D. Meckel's cartilage

- Pinna → Hillcock's (6) = 1st / 2nd arch.
- EAC 1st cleft^{-FA} (arch)
- Middle ear, ET, antrum 1st pouch
- Malleus, incus - Arch 1st
- Stapes - 2nd Arch
- TM -all 3 - VH
- Stapes footplate - otic capsule & / annular lig
- Membranous labyrinth - otic vesicle
- SCC, utricle^{sup} → P S
- Saccule, cochlea → P I

C A P
ect. nerv. ends

50. What is the embryological origin of the cells involved in this condition?

- A. Neural ectoderm
- B. Mesoderm
- C. Surface ectoderm
- D. Neural crest



T1w MRI
melanin ↑

Neural Crest-

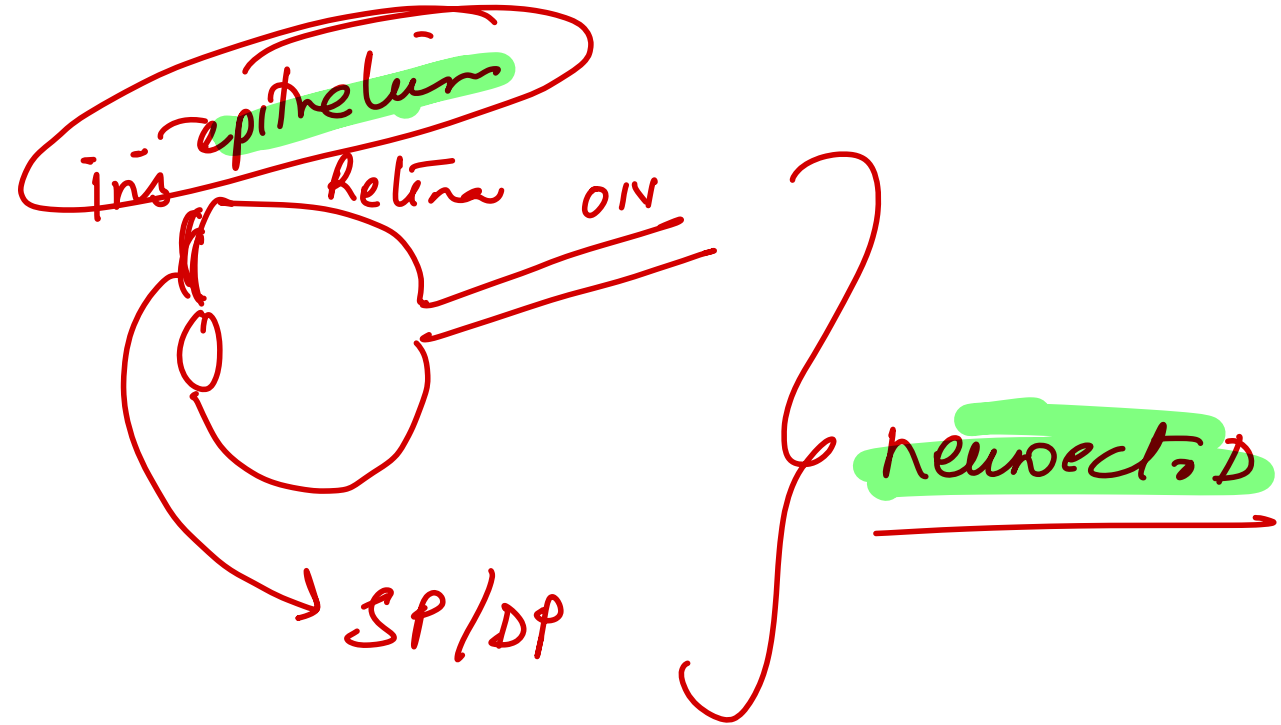
Corneal stroma, endothelium

Sclera (Except superotemporal)

Iris, choroid stroma

Melanocytes

Ciliaris



27. Arrange the following stages of lung development in order from the earliest stage to the latest stage.

1. Canalicular stage

2. Alveolar stage

3. Pseudoglandular stage

4. Saccular stage

A. 3-1-4-2

B. 1-3-2-4

C. 3-4-1-2

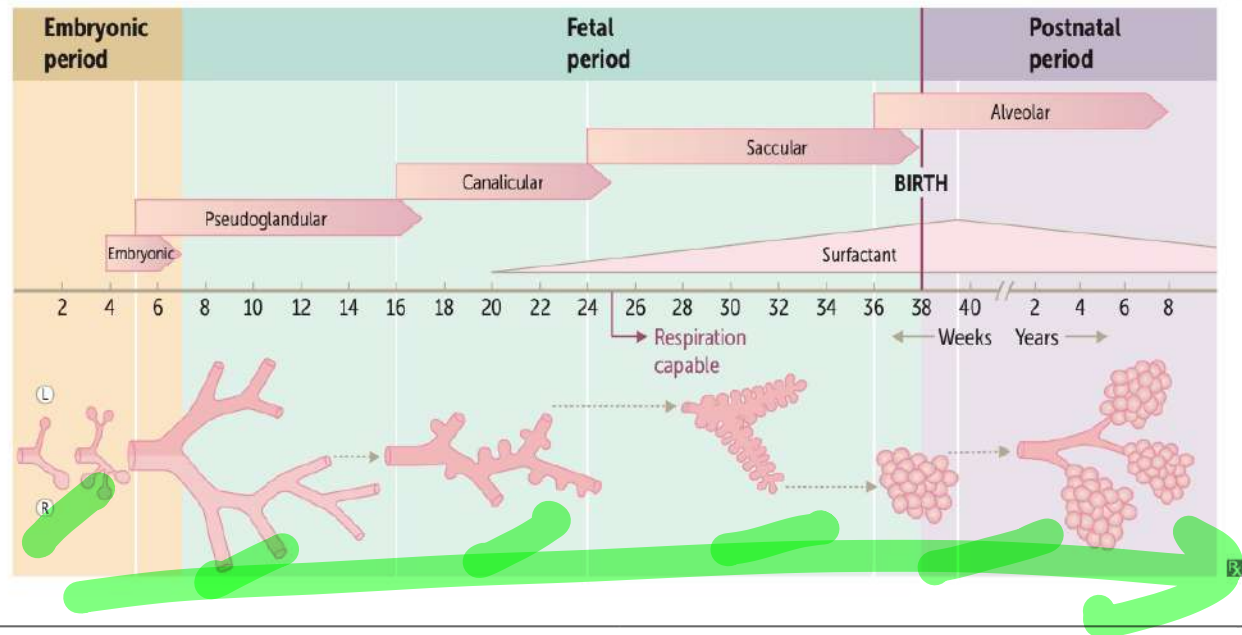
D. 4-3-1-2

STAGE	STRUCTURAL DEVELOPMENT	NOTES
Embryonic (weeks 4-7)	Lung bud → trachea → bronchial buds → mainstem bronchi → secondary (lobar) bronchi → tertiary (segmental) bronchi.	Errors at this stage can lead to <u>tracheoesophageal fistula</u> , <u>tracheal atresia/stenosis</u> and pulmonary agenesis.
Pseudoglandular (weeks 5-17)	Endodermal tubules → terminal bronchioles. Surrounded by modest capillary network.	Respiration impossible, incompatible with life.
Canalicular (weeks 16-25)	Terminal bronchioles → respiratory bronchioles → alveolar ducts. Surrounded by prominent capillary network.	Airways increase in diameter. Pneumocytes develop starting at week 20 (surfactant synthesis). Respiration capable at week 25.
Saccular (week 24-birth)	Alveolar ducts → terminal sacs. Terminal sacs separated by 1° septae.	
Alveolar (week 36-8 years)	Terminal sacs → adult alveoli (due to 2° septation).	In utero, "breathing" occurs via aspiration and expulsion of amniotic fluid → ↑ pulmonary vascular resistance through gestation. At birth, air replaces fluid → ↓ pulmonary vascular resistance.

→ (20) = surfactant begins
why

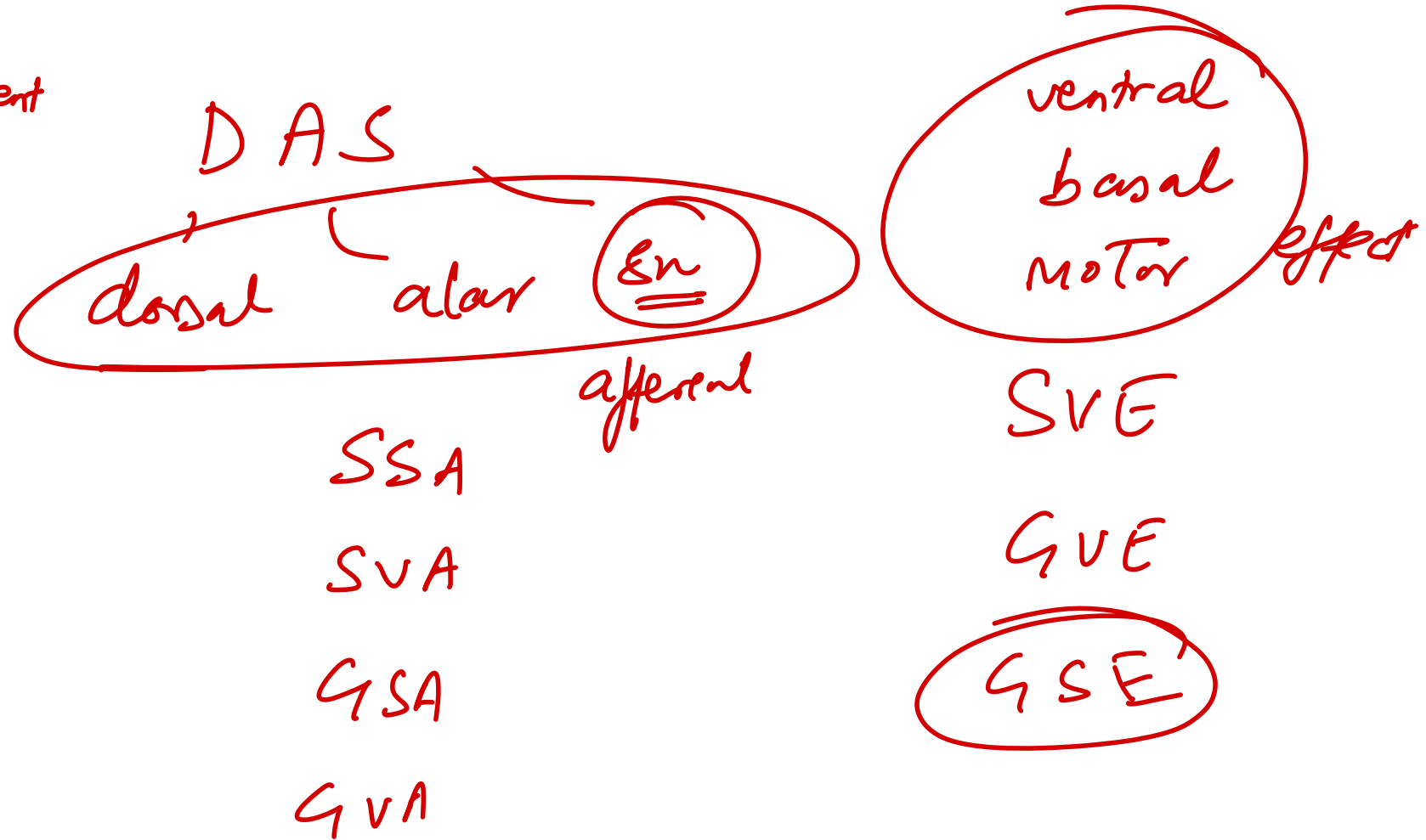
AF: 28 wks

mature: 34 wks →



32. Which of the following brainstem nuclei is not derived from the alar plate?

- A. Inferior olivary → *afferent*
- B. Substantia nigra *aff*
- C. Dentate *aff*
- D. Hypoglossal *motor*



30. In which layer of the cerebral cortex is the outer band of Baillarger seen?

- A. External pyramidal layer
- B. Internal granular layer
- C. Internal pyramidal layer
- D. External granular layer

layers of cx

I Plexiform or molecular		Transverse fibres and some scattered neurons
II External granular		Mainly stellate neurons
III Pyramidal ext		Mainly pyramidal neurons Some stellate cells and basket cells
IV Internal granular		Stellate neurons Outer band of Baillarger
V Ganglionic int pyram		Giant pyramidal cells Inner band of Baillarger
Multiform or polymorphous VI		Neurons of various sizes and shapes Merges with white matter

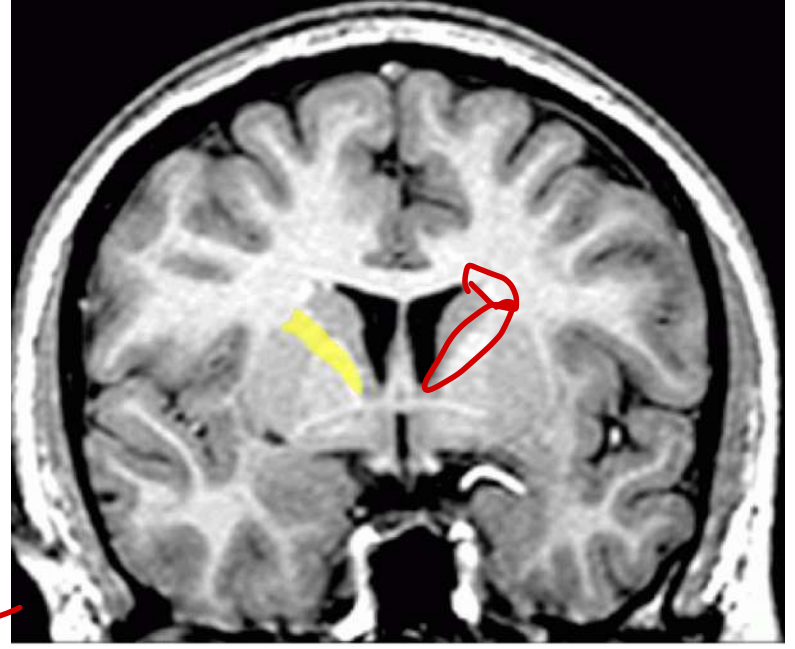
Input from VP2/UPM / LGB
 stripe of Gennari
 naked eye
 → c/s, c/B tract

36. Which of the following is not the blood supply of the marked structure?

- A. Middle cerebral artery
- B. Recurrent artery of Heubner**
- C. Anterior choroidal artery
- D. Posterior cerebral artery

PLIC

Rec artery of Heubner



Sub
Retro
+ ant
Choroidal
A

Genu
Heub
Charcot
Charcot (MCA)
ant choroidal A
PCA ±

37. Which of the following descending tracts in the spinal cord remains uncrossed?

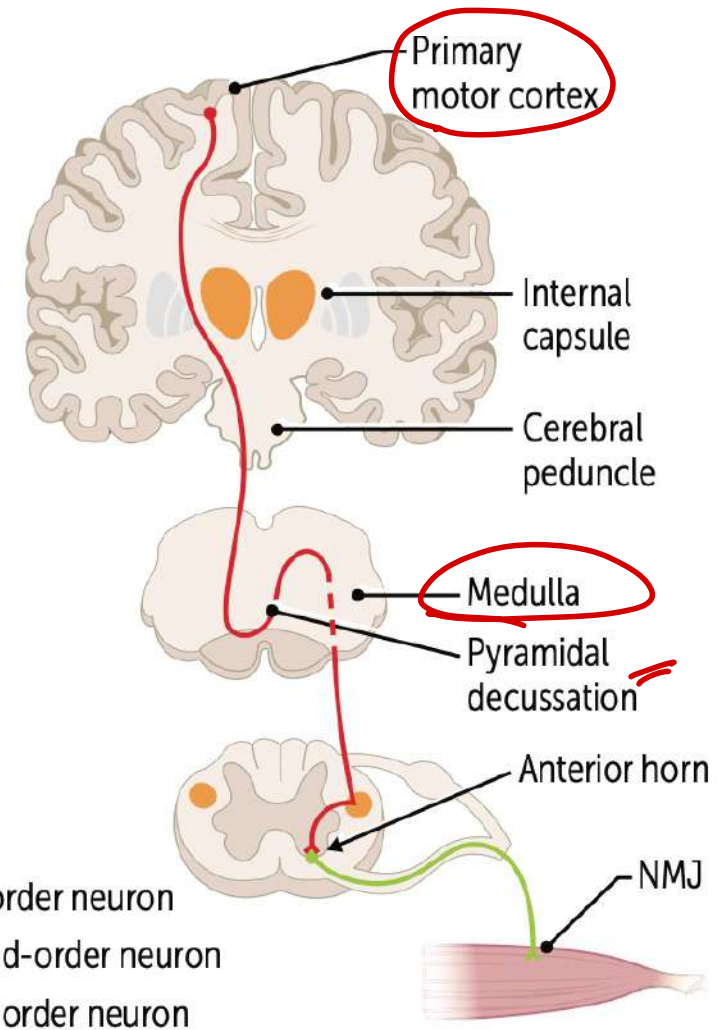
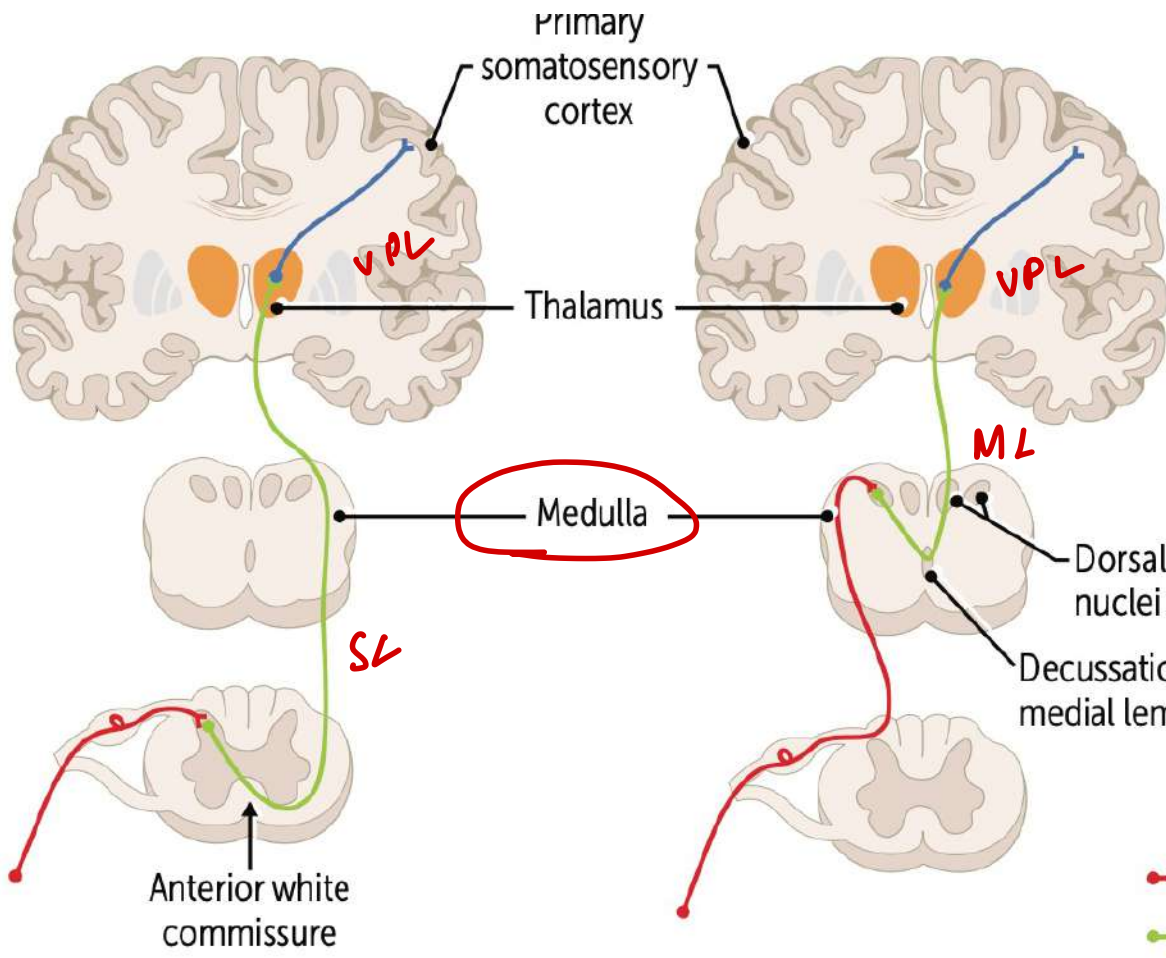
A. Tectospinal tract

B. Rubrospinal tract

~~C. Vestibulospinal tract~~

D. Olivospinal

E. Pyramidal tract (c/s)



- First-order neuron
- Second-order neuron
- Third-order neuron

DC



ascending

38. All of the following tracts pass through inferior cerebellar peduncle except

A. Posterior spinocerebellar ✓

B. Anterior spinocerebellar → SCP

C. Cuneocerebellar ✓

D. Olivocerebellar ✓

linguist
reluculo
vestibulo

SCP

input

ant spinocereb

output

D-R-T tract ***
dentate rubro thalamus
(VA/VL)

MCP

cortico/ponto

=

ICP

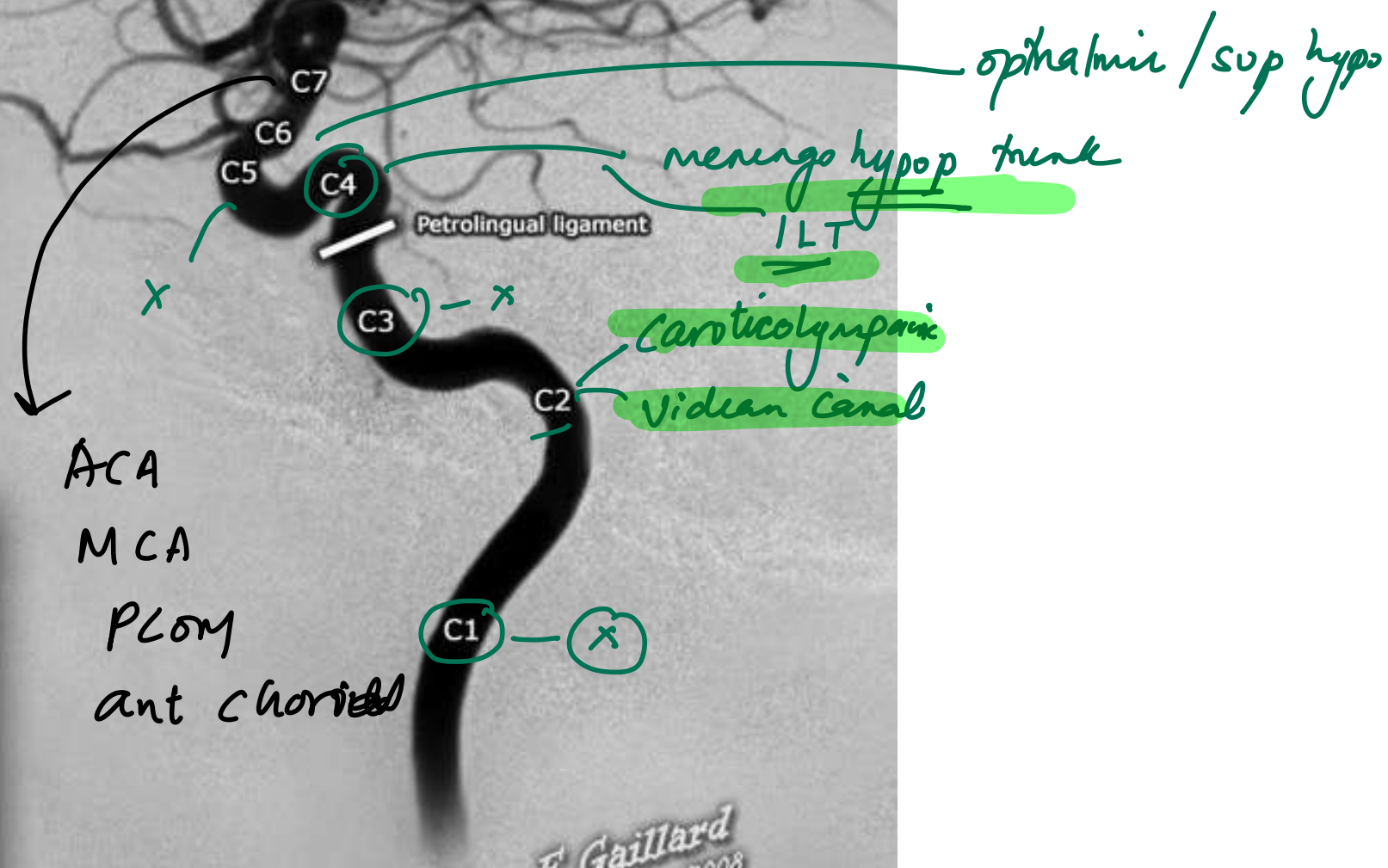
Remaining all ***

fastigial → vestibulo / Reticle

39. Which of the following branches of internal Carotid artery are given off in the cervical region?

- A. Pharyngeal branches
- B. Pterygoid branch
- C. Caroticotympanic branch
- ~~D. None of the above~~

Internal Carotid Artery Segments



Legend	
C1	- cervical
C2	- petrous
C3	- lacerum
C4	- cavernous
C5	- clinoid
C6	- ophthalmic
C7	- communicating

40. Which of the following areas is not a part of anterior neck?

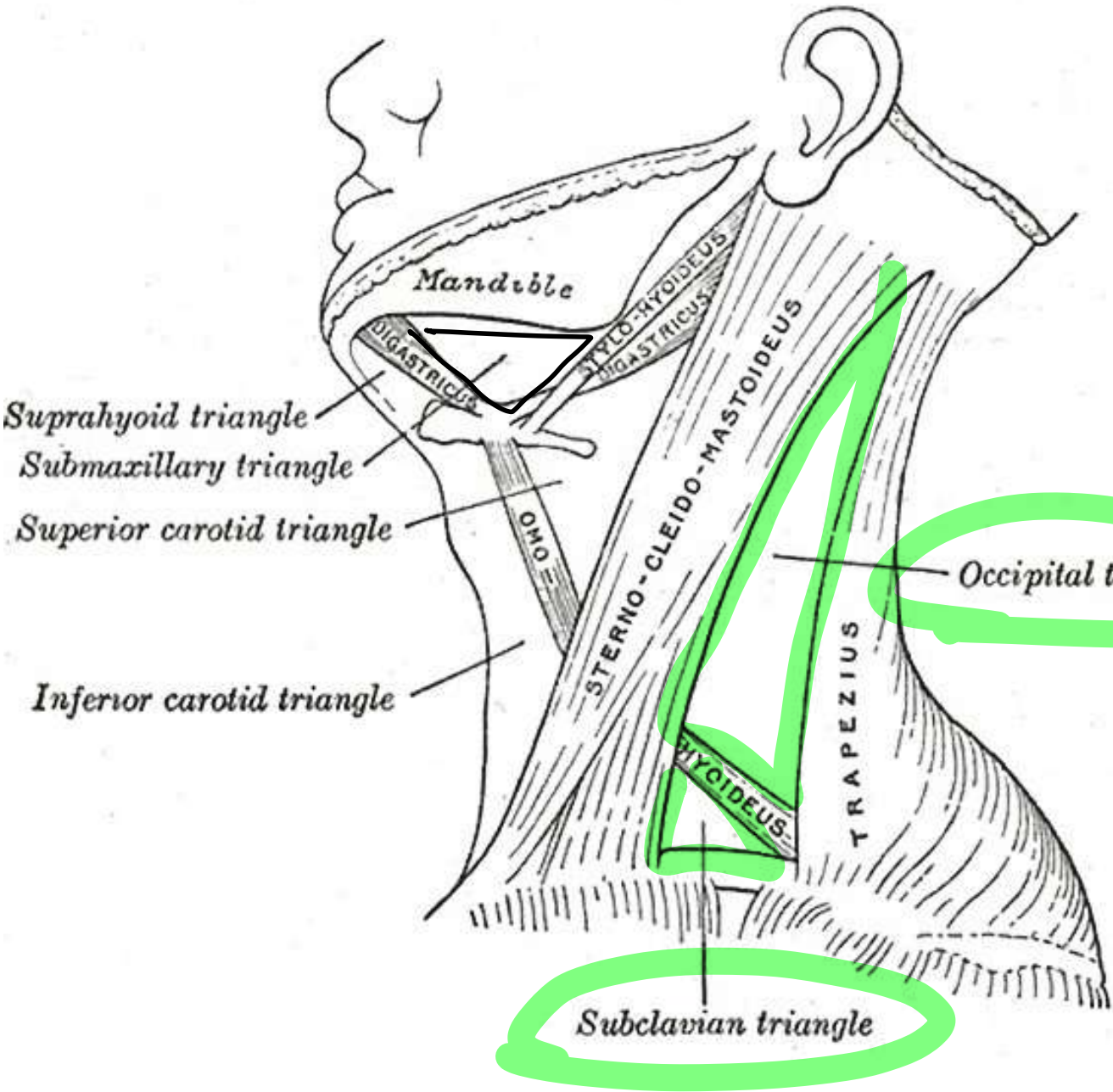
A. Subclavian triangle

B. Submental triangle

C. Digastric triangle

D. Carotid triangle

ant



Post

28. Which of the following properties of the eustachian tube predisposes to higher incidence of acute otitis media in children than adults?

- A. More angulated at isthmus *- adult*
- B. Rigid cartilage *- adult*
- C. Dense elastin in the cartilage *- adult*
- D. Wider and shorter tube

Ostmann's pad of fat ↓ in infants

7. Which of the following blood vessels does not contribute to the blood supply of the abnormal structure?

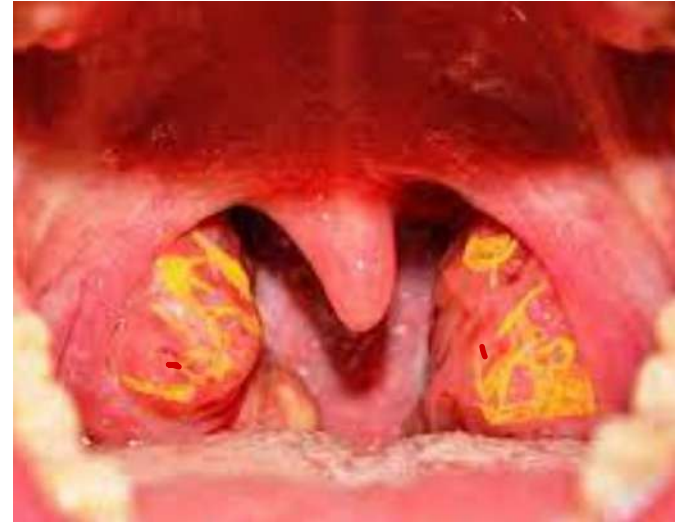1. Internal carotid artery ✘✘
2. External carotid artery ✓
3. Facial artery ✓
4. Lingual artery ✓
5. Maxillary artery ✓

A. 1 only

B. 1 and 5

C. 1 and 3

D. 3, 4 and 5



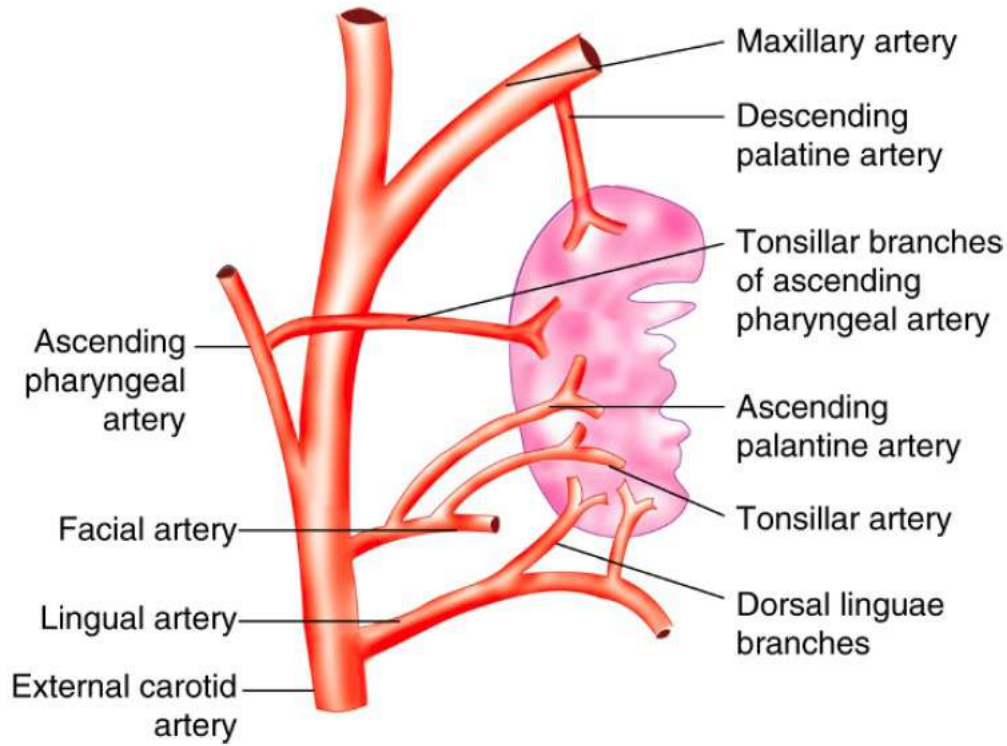


Figure 51.3. Arterial supply of tonsil.

The tonsil is supplied by five arteries (Figure 51.3).

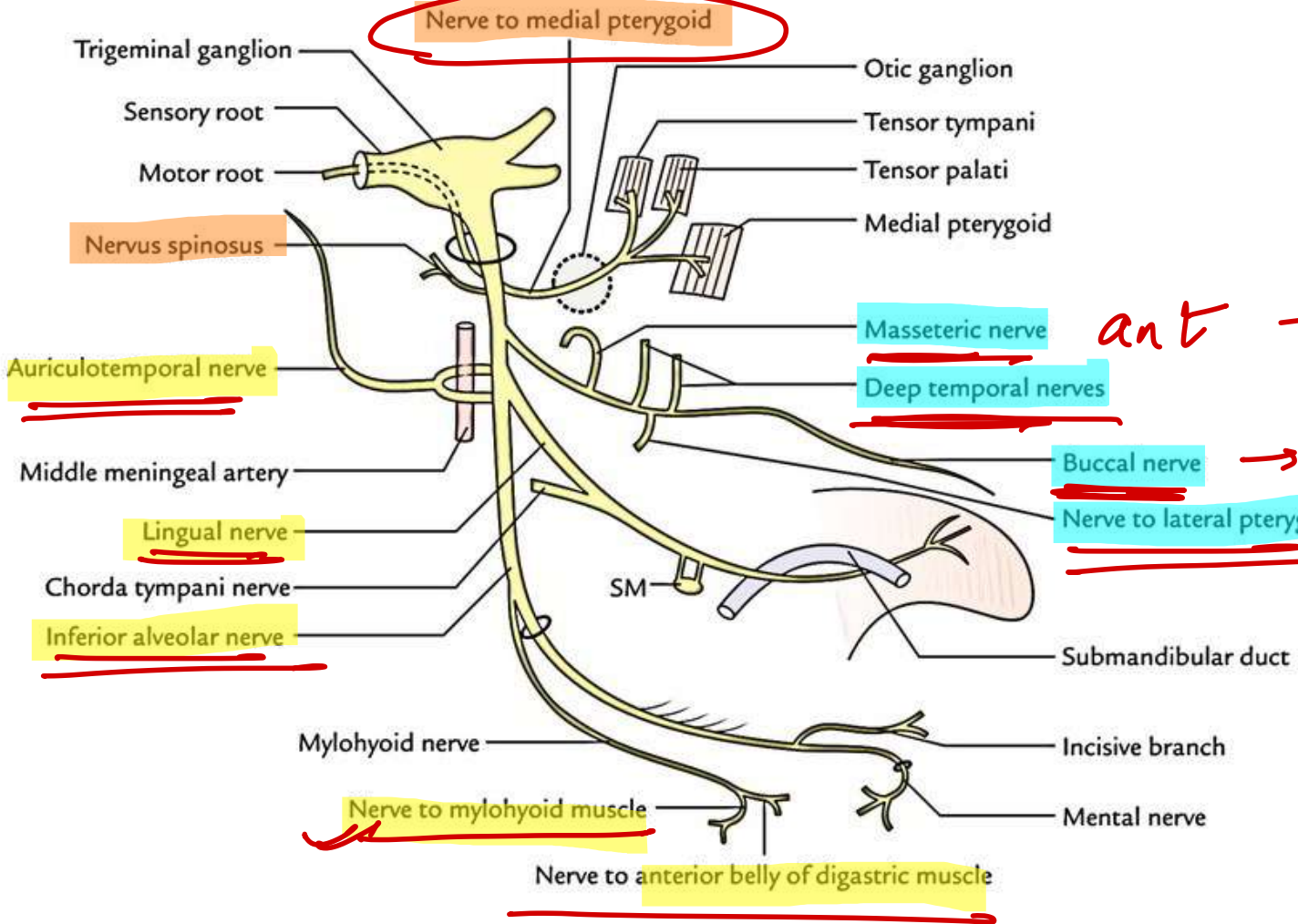
1. Tonsillar branch of facial artery. This is the main artery.
2. Ascending pharyngeal artery from external carotid.
3. Ascending palatine, a branch of facial artery.
4. Dorsal linguae branches of lingual artery.
5. Descending palatine branch of maxillary artery.

25. A 40-year-old man presents with difficulty chewing on one side. On examination, there is reduced movement of the mandible due to impaired muscle function. Which of the following nerves, a branch of the anterior division of the mandibular nerve, is most likely affected?

- A. Masseteric
- B. Lingual
- C. Auriculotemporal
- D. Meningeal

V₃

main trunk



post ÷

ALI

ant ÷

SN

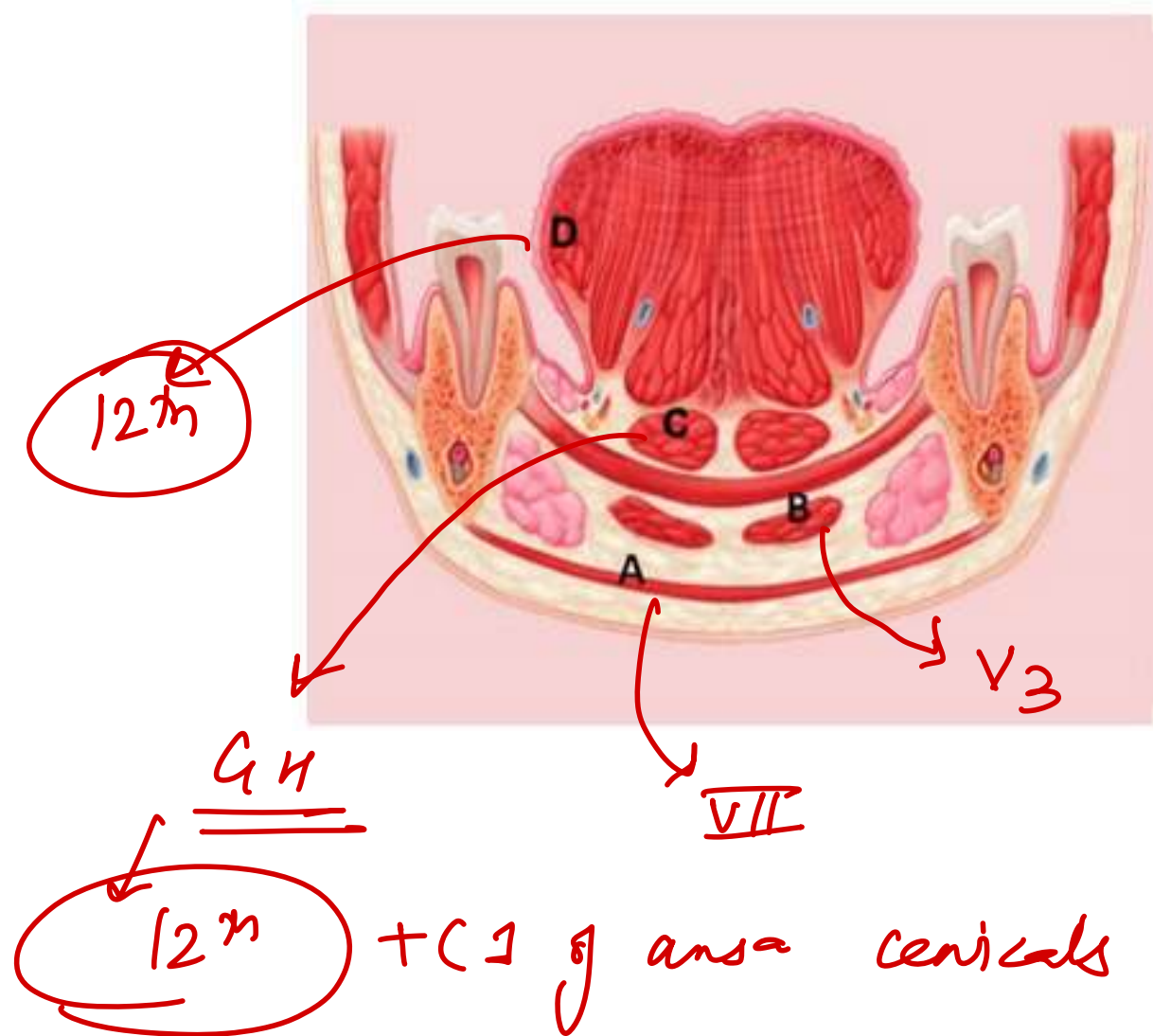
62. Identify the incorrectly matched pair with respect to its nerve supply of the marked structures in the given image:

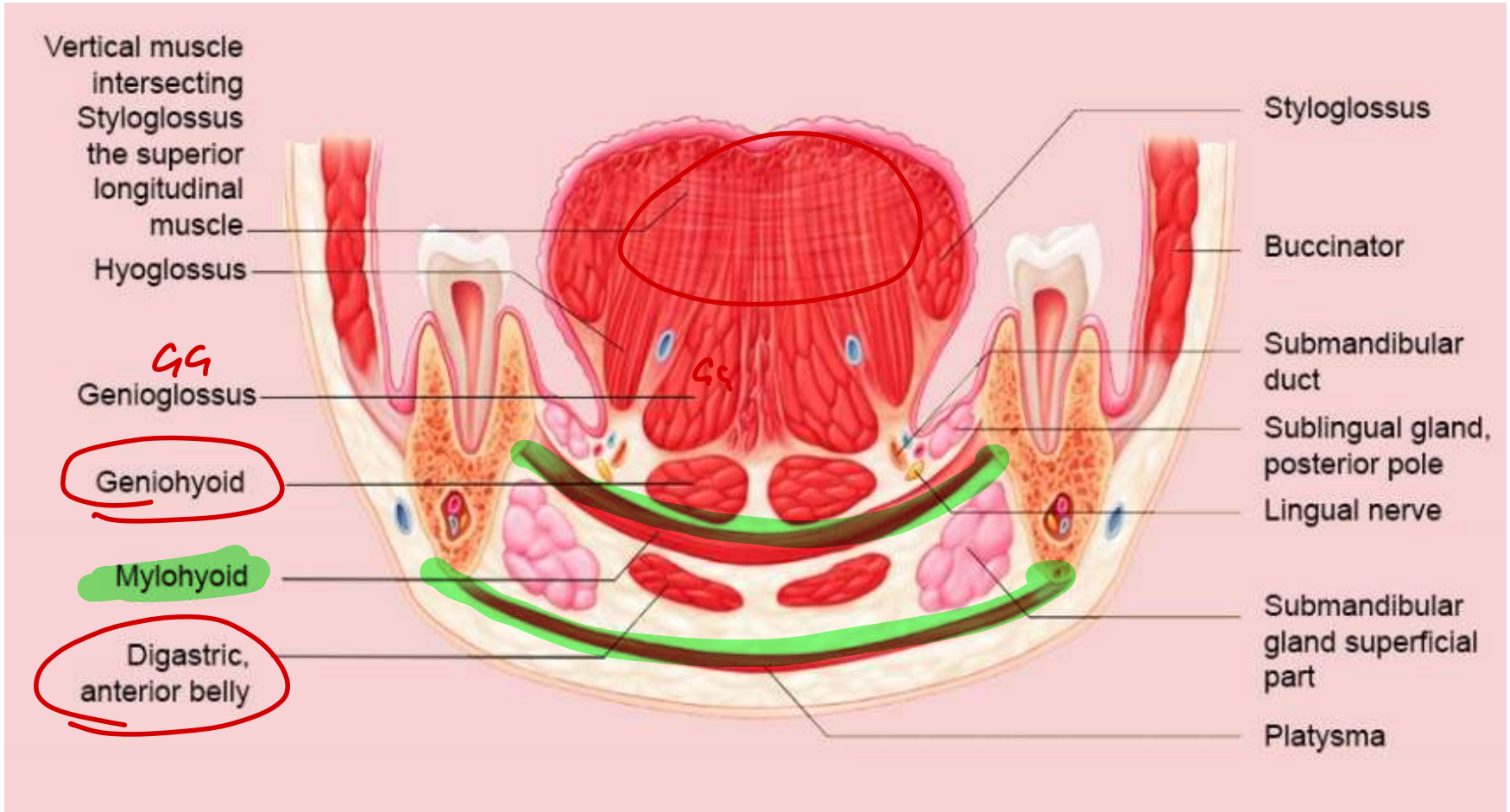
A) Facial Nerve

B) Trigeminal Nerve

~~C) Glossopharyngeal Nerve~~

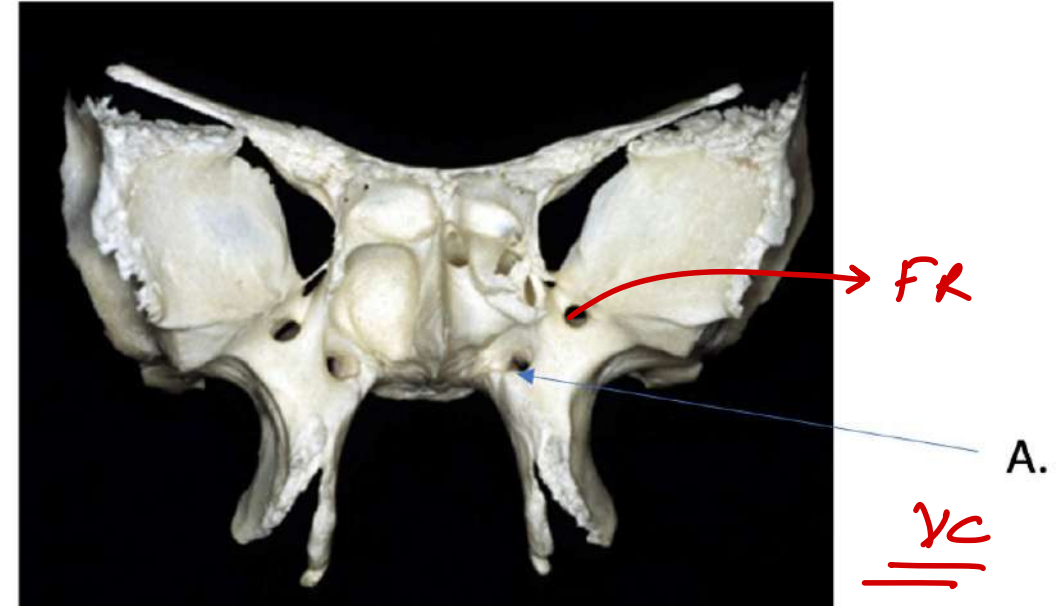
D) Hypoglossal Nerve



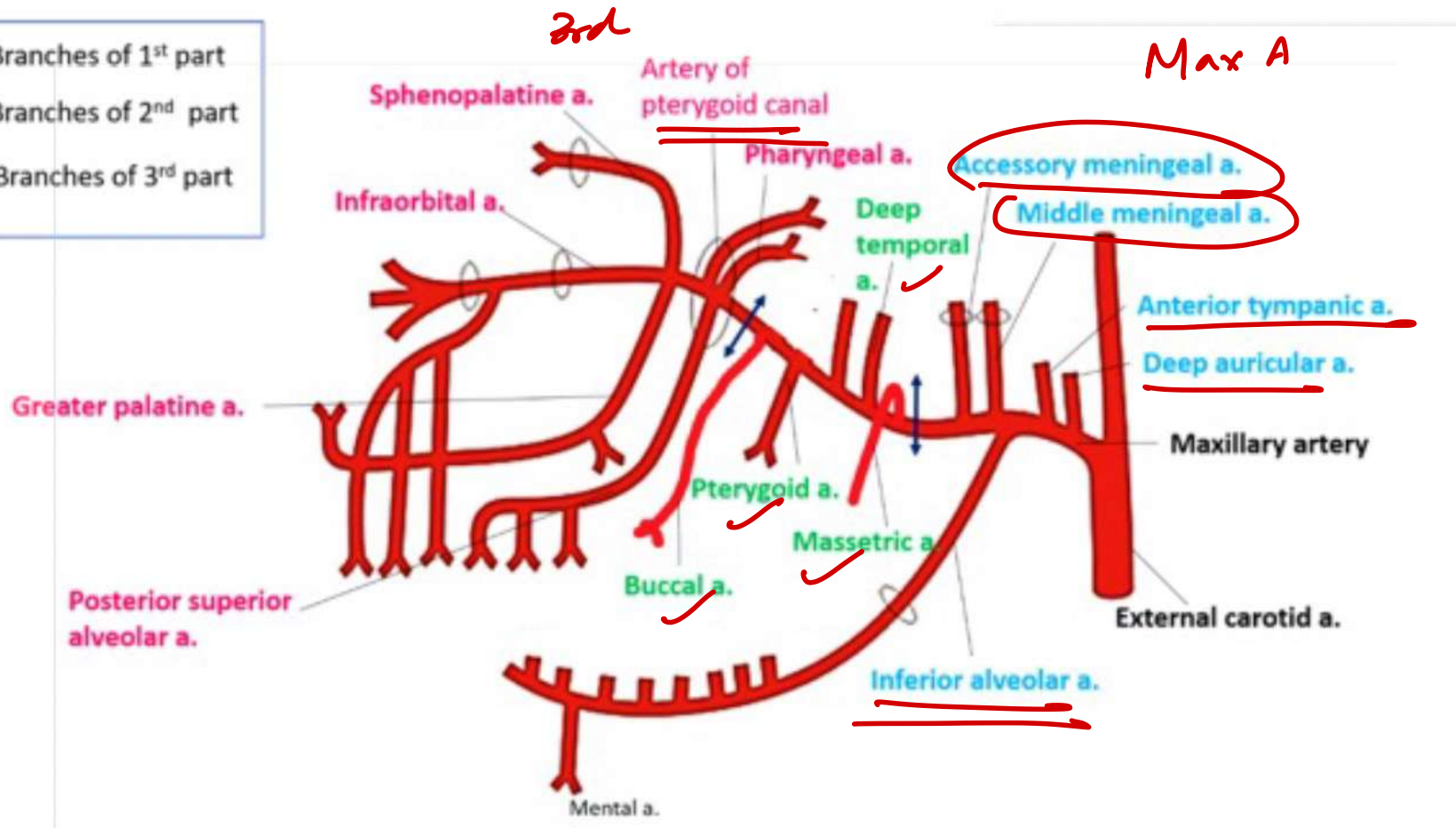


43. The artery passing through the structure marked A is a branch of which part of the maxillary artery?

- A. First part
- B. Second part
- ~~C. Third part~~
- ~~D. Fourth part~~



- Branches of 1st part
- Branches of 2nd part
- Branches of 3rd part



42. Which of the following muscle causes opening of laryngeal inlet?

A. Vocalis

B. Thyroepiglotticus

C. Cricothyroid

D. Thyroarytenoid

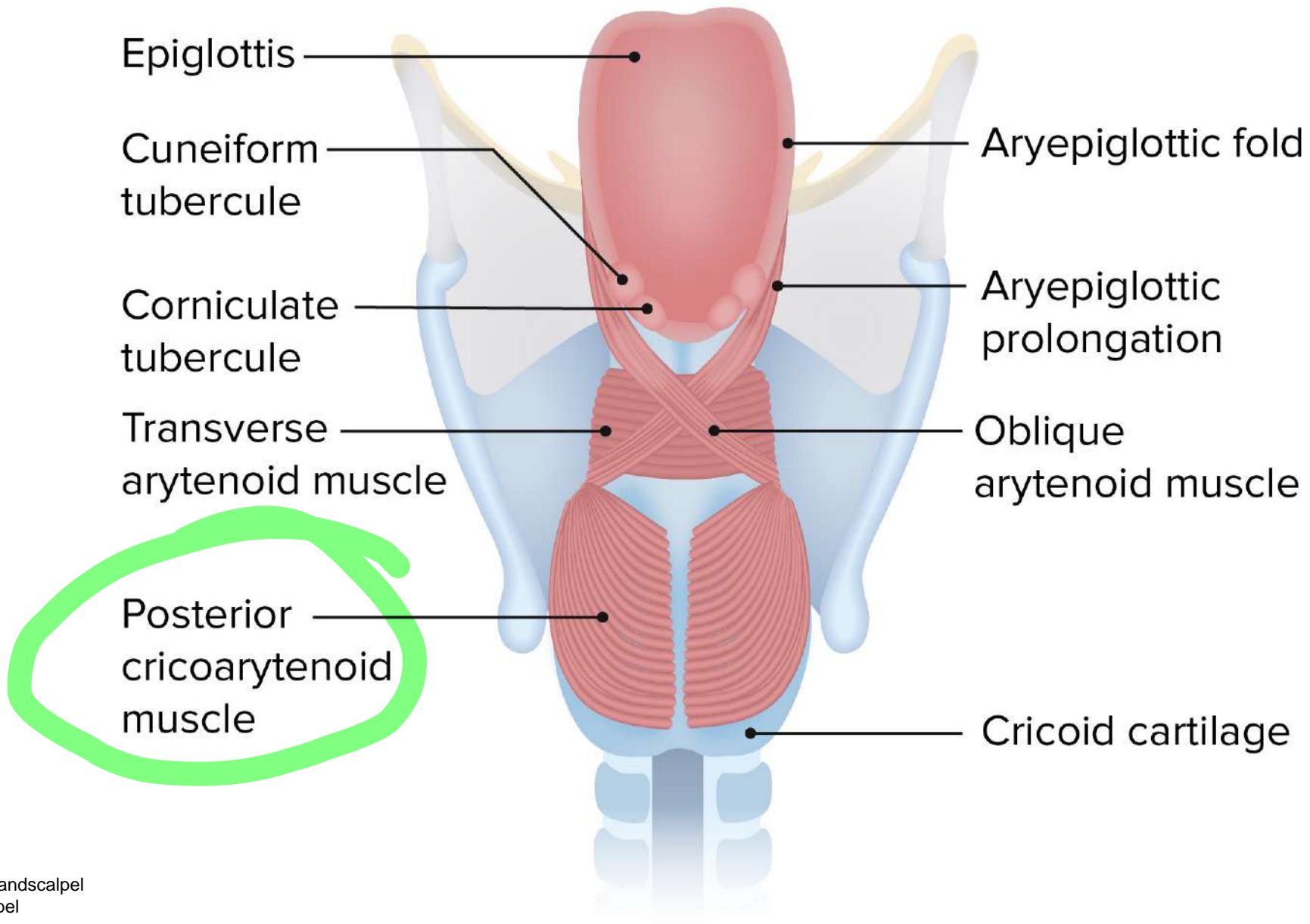
Muscles acting on the larynx

Movement	Muscle
Elevation of larynx	Thyrohyoid, mylohyoid
Depression of larynx	Sternohyoid, sternothyroid
Opening inlet of larynx	Thyroepiglottic
Closing inlet of larynx	Aryepiglottic
Abductor of vocal cords	Posterior cricoarytenoid only
Adductor of vocal cords	Lateral cricoarytenoid (whisper), transverse and oblique arytenoids
Tensor of vocal cords	Cricothyroid
Relaxor of vocal cords	Thyroarytenoid and <u>vocalis</u> (modulator)

safety

TAD

tensor relaxor



41. A 40-year-old man with a history of tobacco chewing presented with a non-healing ulcer over the tip of the tongue. Biopsy revealed squamous cell carcinoma. Which of the following would be the sentinel lymph nodes?

A. Submandibular lymph nodes

~~B. Submental lymph nodes~~

C. Deep cervical lymph nodes

D. Jugulo-omohyoid lymph nodes

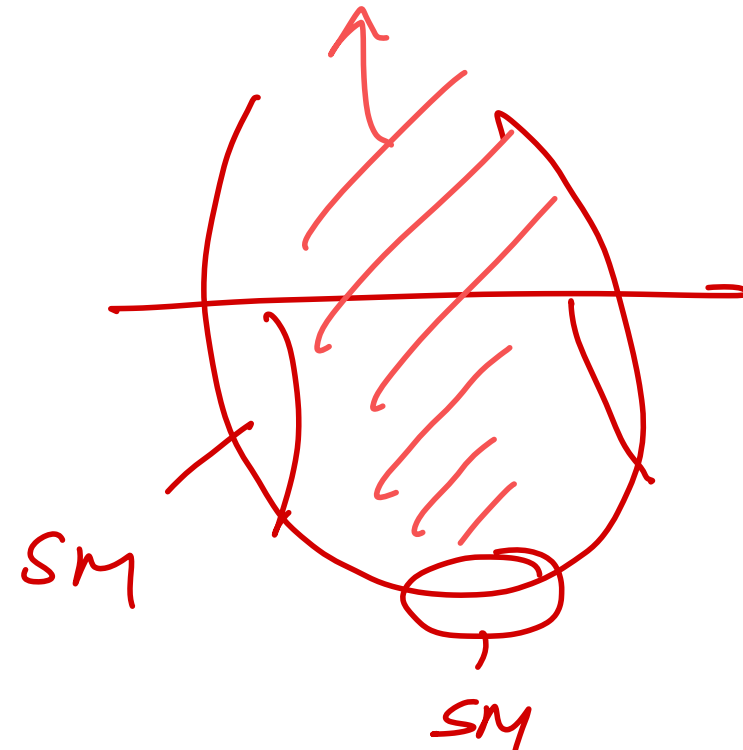
→ ant 2/3 tongue marginal

-Tip

→ Root (level 2)

JO / JD

→ ant 2/3 central
→ post 1/3



48. A pedestrian crossing the road is met with a road traffic accident. He has presented to the emergency with left foot drop. Power in tibialis anterior, extensor digitorum longus, and extensor hallucis longus is 0/5. While power in tibialis posterior, gastrocnemius is 4/5. What is the likely site of injury?

A. Supracondylar fracture of left femur

B. Fracture neck of left fibula

C. Posterior dislocation of femur head

D. Left ankle fracture

CPN → DPN

Nerve	Muscle Group	Muscles Supplied	Main Actions
Superficial Peroneal Nerve (SPN)	Lateral compartment of leg	- Peroneus (Fibularis) longus- Peroneus (Fibularis) brevis	<u>Eversion of foot</u>
Deep Peroneal Nerve (DPN)	Anterior compartment of leg <i>THAND</i>	- Tibialis anterior- Extensor hallucis longus- Extensor digitorum longus- <u>Peroneus</u> (Fibularis) <u>tertius</u>	<u>Dorsiflexion of ankle</u> <u>Toe extension</u>
	Dorsum of foot	- Extensor digitorum brevis- Extensor hallucis <u>brevis</u>	<u>Extension of toes</u>
Tibial Nerve	Posterior compartment of leg (superficial)	- Gastrocnemius- Soleus- Plantaris	<u>Plantarflexion of foot</u>
	Posterior compartment of leg (deep)	- Popliteus- Flexor digitorum longus- Flexor hallucis longus- Tibialis posterior	<u>Plantarflexion, toe flexion,</u> <u>inversion</u>
	Sole of foot (via medial plantar nerve)	- <u>Abductor hallucis</u> - <u>Flexor</u> digitorum brevis- <u>Flexor hallucis</u> brevis- <u>1st lumbrical</u> <i>LAPP</i>	Toe flexion, abduction of hallux
	Sole of foot (via lateral plantar nerve)	- Abductor digiti minimi- Quadratus plantae- 2nd-4th lumbricals- Adductor hallucis- Flexor digiti minimi brevis- Interossei (dorsal & plantar)	Toe abduction/adduction, lateral toe flexion

SGN: *Gl. medius, minimus, TFL*
N to OI: *SG*
N to piriformis: *Piriformis*
IGN: *Gl. maximus*
N to QF: *IQ*

QA

46. Which of the following muscles causes external rotation of the hip joint?

- A. Gluteus medius → Abductor + IR
- B. Gluteus maximus → Extension + ABER
- C. Tensor fascia lata → IR
- D. Adductor longus → adductor

flexor: iliopsoas -

Nerve	Muscle Supplied
<u>Median nerve</u>	Pronator teres ^{QQ} <u>PM</u>
	Flexor carpi radialis (FCR)
	<u>Palmaris longus</u>
	Flexor digitorum superficialis (FDS)
	Thenar muscles (except adductor pollicis)
	1st and 2nd lumbricals
<u>AIN</u>	<u>Flexor pollicis longus (FPL)</u>
	<u>Pronator quadratus</u>
	<u>Lateral half of FDP (index, middle)</u>

Muscles Supplied by Ulnar Nerve

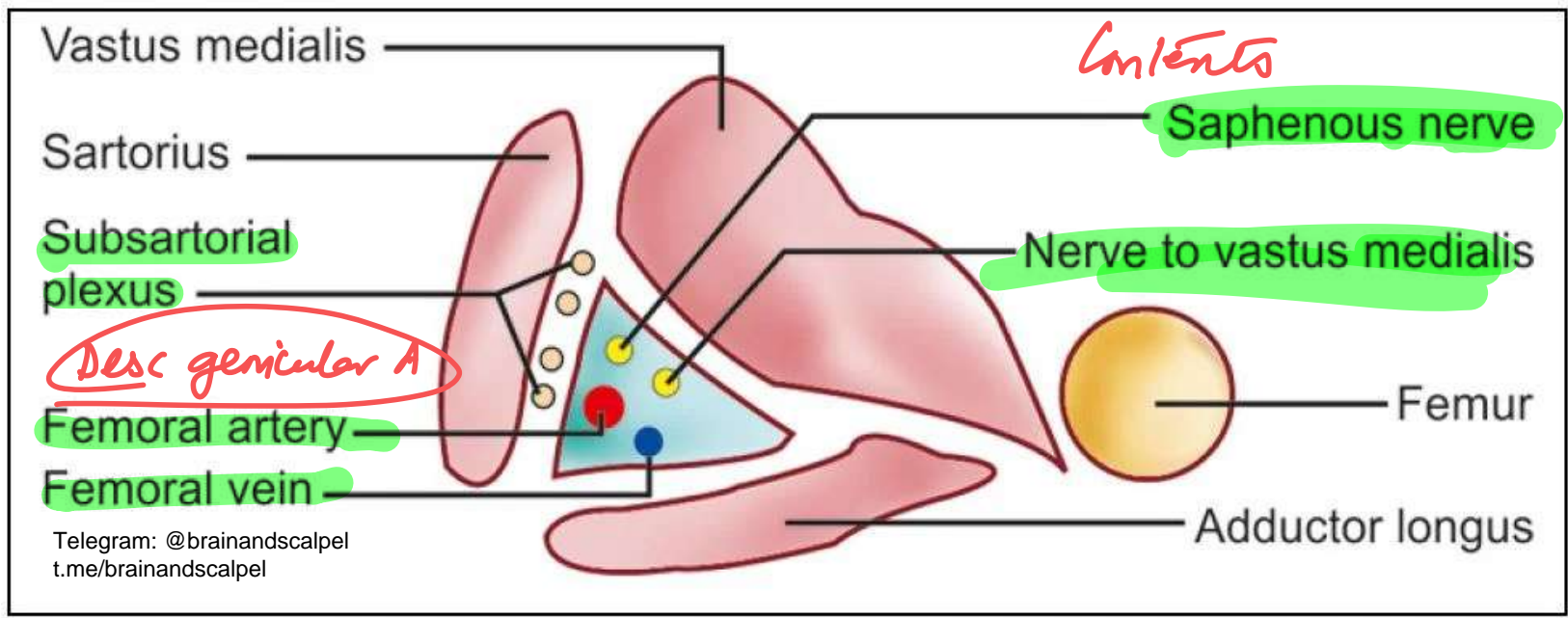
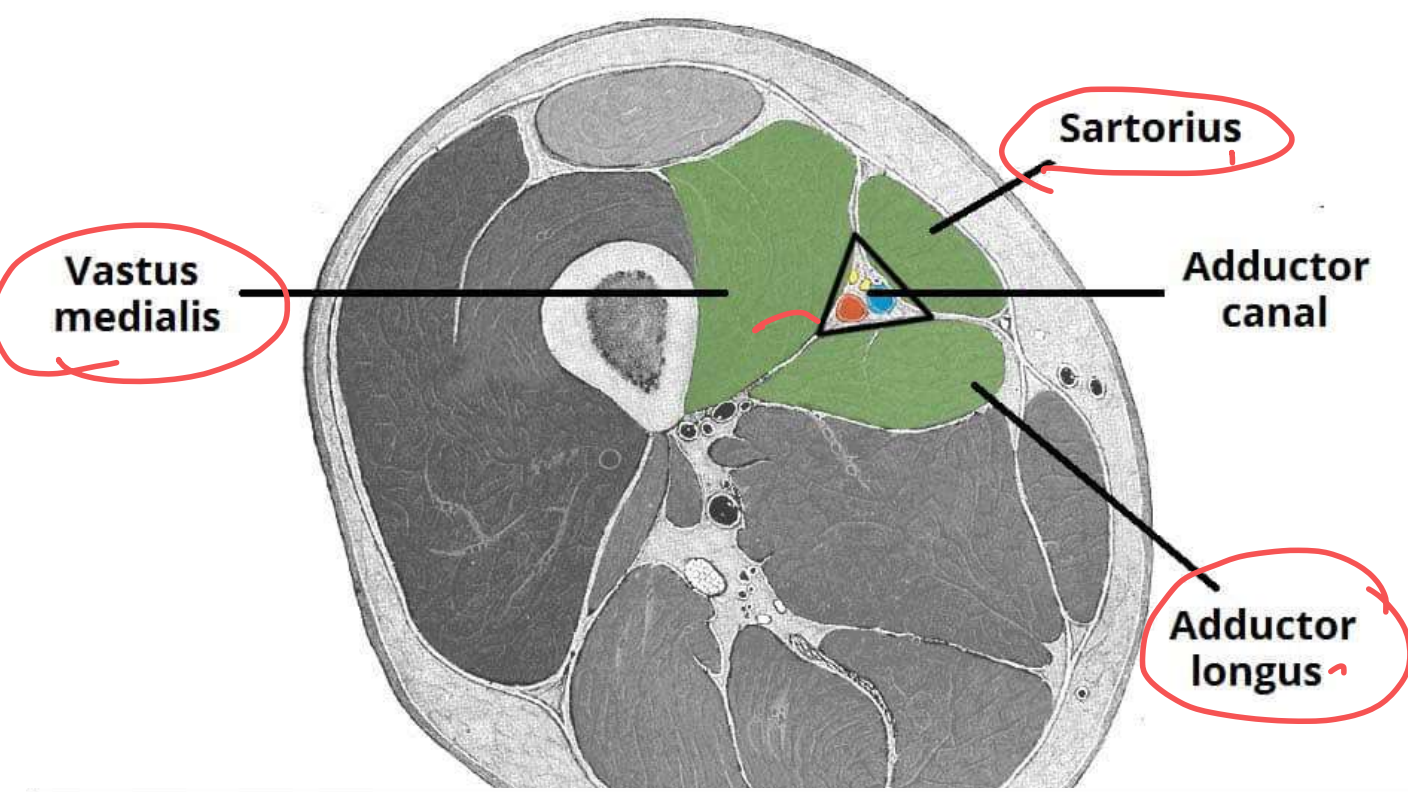
Flexor carpi ulnaris, medial half of FDP
 Hypothenar group, medial 2 lumbricals, all interossei, adductor pollicis, deep head of FPB, palmaris brevis

Sup: median N

Ulnar N

47. The hunter's canal lies beneath which muscle?

- A. Vastus medialis
- B. Adductor longus
- C. Sartorius
- D. Adductor magnus



49. Which of the following structures do not pass through both greater and lesser sciatic foramina?

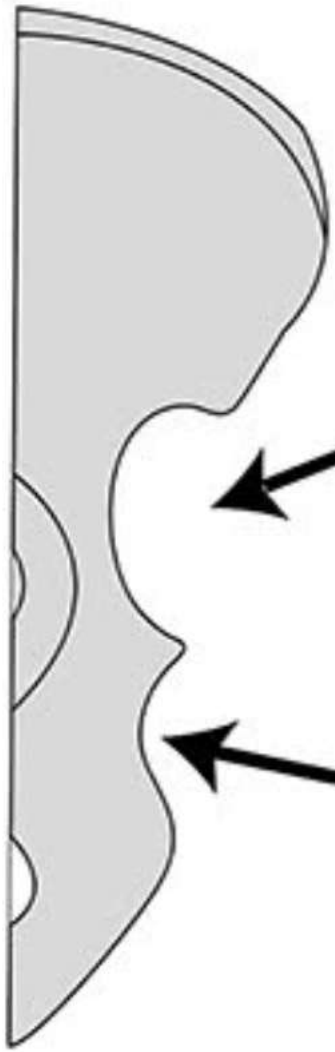A. Pudendal nerve

~~B. Tendon of obturator internus~~ — lesser

C. Nerve to obturator internus

D. Internal pudendal vessels

STRUCTURES PASSING THROUGH THE GREATER & LESSER SCIATIC FORAMINA



VIA GREATER SCIATIC FORAMEN

- Superior gluteal vessels
- Superior gluteal nerve

PIRIFORMIS

- Inferior gluteal vessels
- Inferior gluteal nerve
- Sciatic nerve ✓
- Perforating cutaneous nerve ✓
- Posterior femoral cutaneous nerve ✓
- Nerve to quadratus femoris ✓
- Nerve to obturator internus ✓
- Pudendal nerve
- Internal pudendal vessels

VIA LESSER SCIATIC FORAMEN

- Tendon of obturator internus
- Nerve to obturator internus
- Internal pudendal vessels
- Pudendal nerve

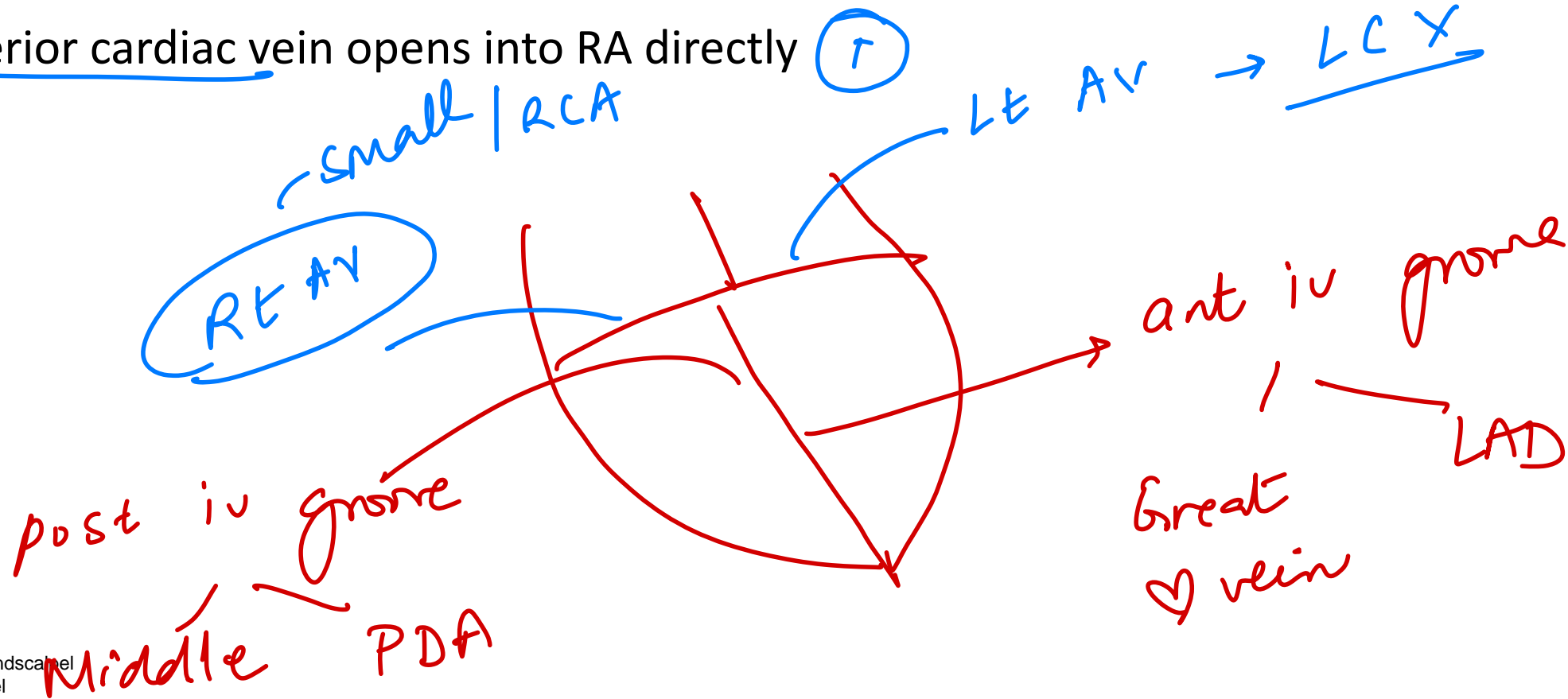
Handwritten notes and markings:

- Double lines next to Superior gluteal vessels
- Checkmarks next to Sciatic nerve, Perforating cutaneous nerve, Posterior femoral cutaneous nerve, and Nerve to quadratus femoris
- Handwritten 'IS' and 'S9' with arrows pointing to Nerve to quadratus femoris and Nerve to obturator internus respectively.

Handwritten note: P1N = = =

26. Which among the following is wrong about the venous drainage of the heart?

- A. Coronary sinus is guarded by the thebesian valve (CT)
- ~~B. Middle cardiac vein lies in the posterior atrioventricular groove (F)~~
- C. Great cardiac vein accompanies left anterior descending artery (T)
- D. Anterior cardiac vein opens into RA directly (T)



29. You should not insert the needle below which level in midaxillary line so as not to damage the liver?

- A. 6th rib
- B. 10th rib
- C. 8th rib
- D. 12th rib

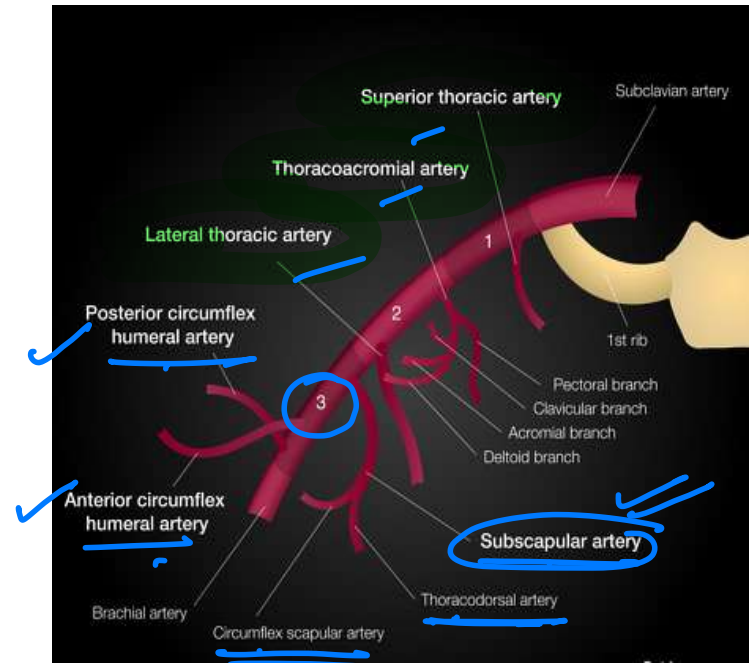
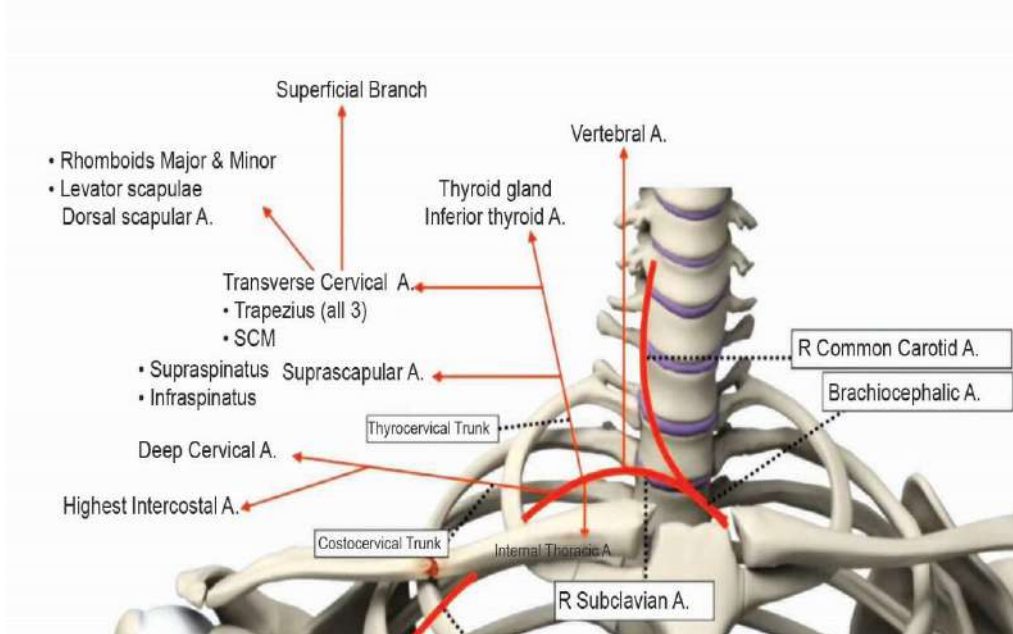
8 - 10

lung *Pleural recess*
Lower
Midclavicular line: 6th rib-8th rib
Mid-axillary line: 8th rib-10th rib
Paravertebral line: 10th rib-12th rib

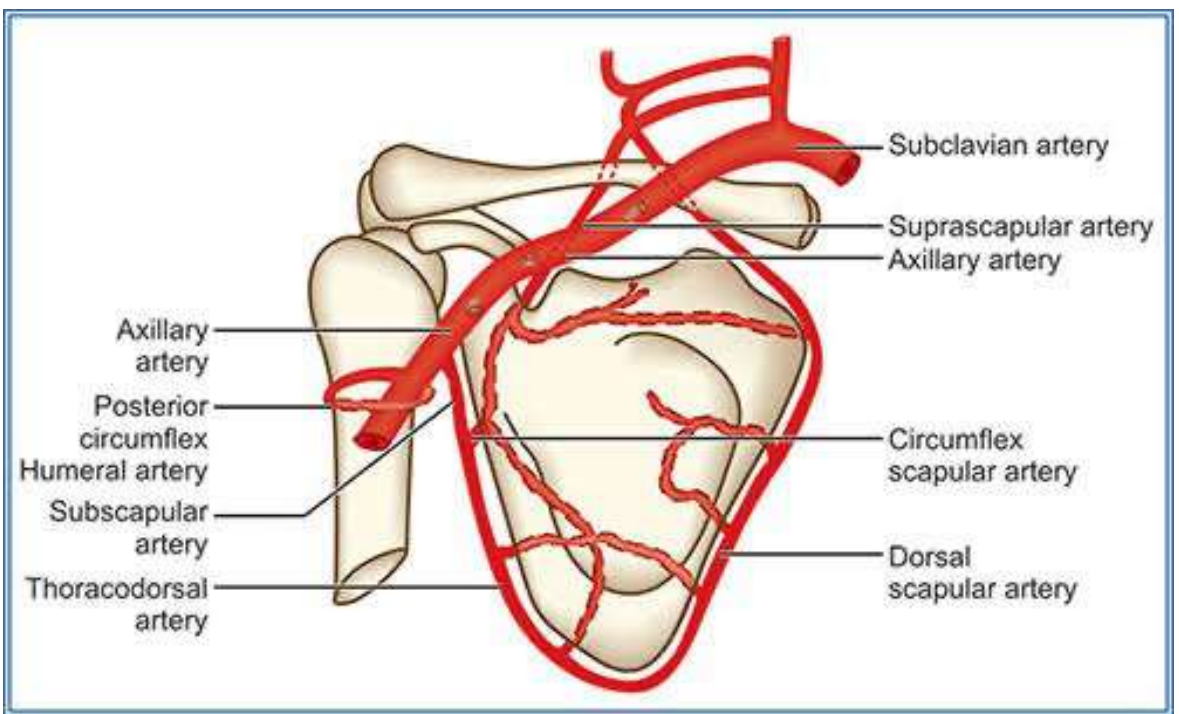
6 8 10 12
— —

24. Which of the following arteries does not contribute to the scapular anastomosis?

- a • Lateral thoracic artery
- b • Transverse cervical artery
- c • Subscapular artery
- d • Suprascapular artery



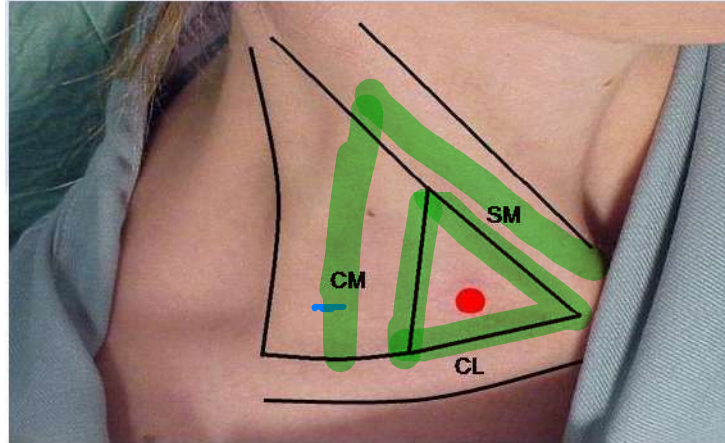
SALT SPA



77. A 35-year-old patient is scheduled for central venous catheter placement. The anesthesiologist discusses the landmarks used to identify the internal jugular vein for cannulation. Which of the following surface landmarks is used for this purpose?

- Subclavian triangle
- Sedillot's triangle
- Scapulo Vertebral triangle
- Suboccipital triangle

Triangle of Sedillot



19. Identify the tributaries of the vessel marked in the image except:

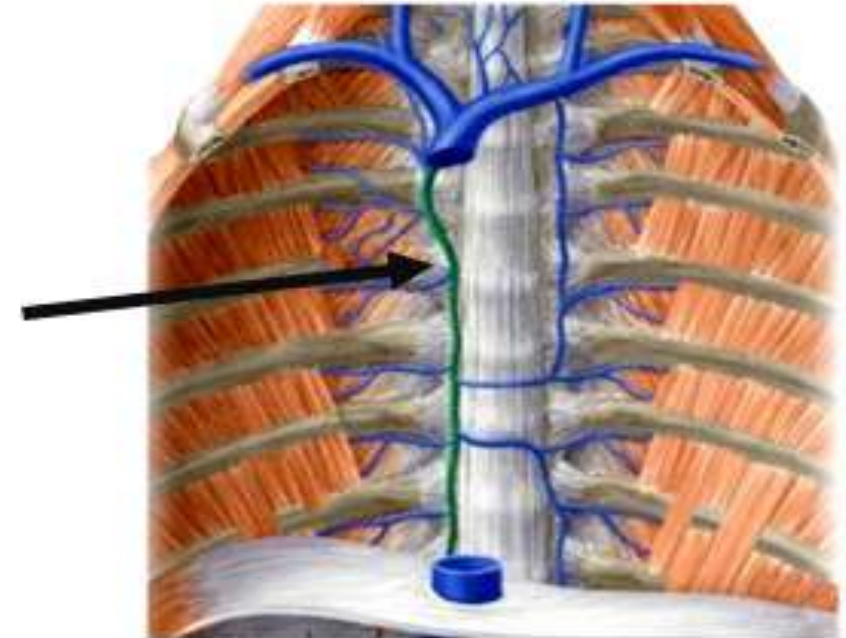
- Right ascending lumbar ✓
- Right subcostal vein ✓
- Right 5th posterior intercostal vein ✓
- ~~Left 5th posterior intercostal vein~~ ✓

5-11

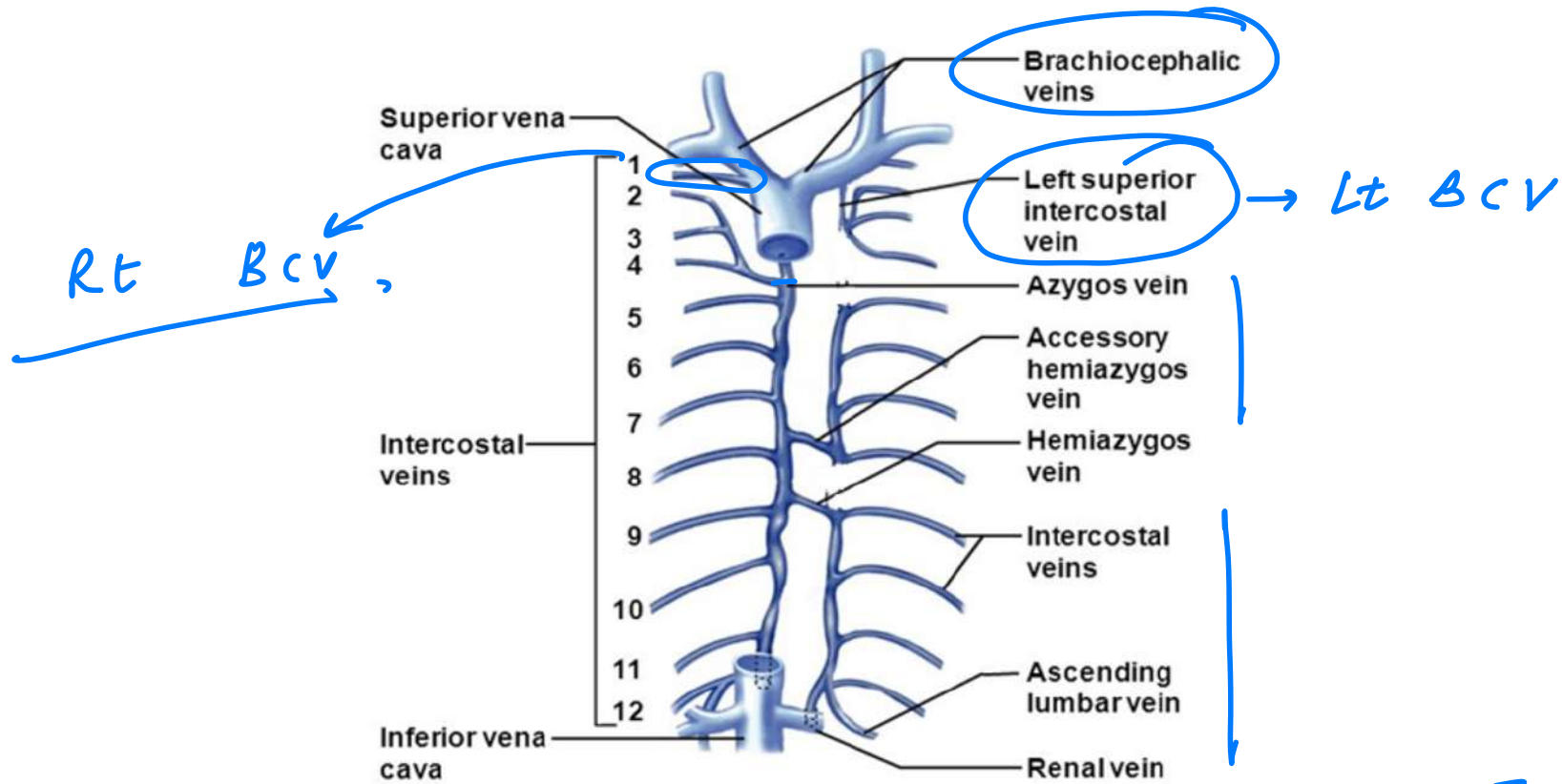


Acc hem

5-6-7-8



Hemi : 9-12



Azygos

Formed by: Right Lumbar azygos, right subcostal, right ascending lumbar

Tributaries:

Right superior intercostal vein: 2,3,4 PICV

Right 5-11th PICV

Hemiazygos, Accessory hemiazygos-T8

14 -> SVC

Hemiaz

Formed by: left Lumbar azygos, left subcostal, left ascending lumbar

Tributaries:

Left 9-11th PICV

Acc hemiaz

Tributaries:

Left 5-8^h PICV

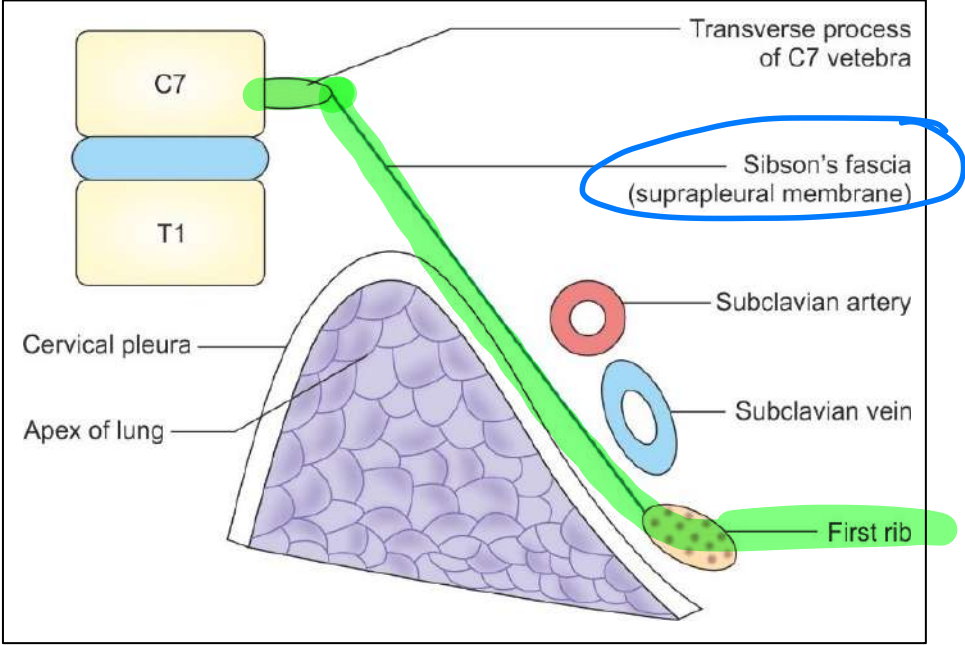
37. The largest lymphatic duct of our body opens into the systemic circulation at which of the following locations?

- A. Junction of superior vena cava and left brachiocephalic vein
- B. Junction of left internal jugular and left subclavian vein
- C. Directly into coronary sinus
- D. Into the azygos vein

Feature	Details
Length	45 cm (18 inches)
Origin	Continuation of <u>cisterna chyli</u> near the lower border of T12 vertebra <i>AAT 12</i>
Course	Ascends through the posterior mediastinum, crosses to the left at T5. <u>arches at C7</u>
Drainage Point	Junction of left internal jugular and left subclavian veins
Drainage Territory	Entire body below the diaphragm and left half of the body above the diaphragm

193. A 35-year-old construction worker presents with pain and swelling in the lower neck following a fall from a height. He reports difficulty breathing, and on examination, there is reduced air entry over the right lung apex. A CT scan reveals herniation of the cervical pleura into the lower neck, suggesting an injury to a fascial structure that protects the lung apex and separates the neck from the thoracic cavity. Which of the following statements regarding this fascial structure is **incorrect?**

- A. ~~Attached to the inner border of the 2nd rib~~ ^{1st}
- B. Covers the apical part of the lung
- C. Part of the scalenus minimus muscle
- D. Vessels pass above the fascia



39. Which of the following statements about the lienorenal (splenorenal) ligament are correct?

A. It connects the spleen to the kidney. (T)

B. It contains the splenic artery and vein. (T)

C. It contains the short gastric arteries. — *Gastric & splenic*

D. It encloses the tail of the pancreas. (T)

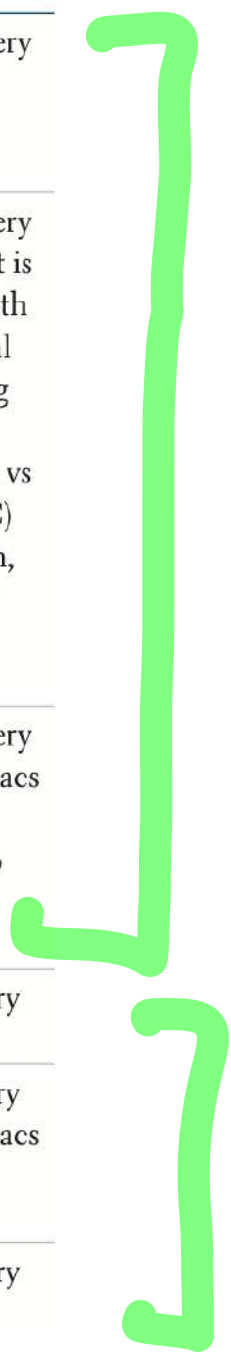A. A and B only

~~B. A, B, and D only~~

C. A, C, and D only

D. All of the above

LIGAMENT	CONNECTS	STRUCTURES CONTAINED	NOTES
Falciform ligament	Liver to anterior abdominal wall	Ligamentum teres hepatis (derivative of fetal umbilical vein), patent paraumbilical veins	Derivative of ventral mesentery
Hepatoduodenal ligament	Liver to duodenum	Portal triad: proper hepatic artery, portal vein, common bile duct	Derivative of ventral mesentery Pringle maneuver —ligament is compressed manually or with a vascular clamp in omental foramen to control bleeding from hepatic inflow source (portal vein, hepatic artery) vs outflow (hepatic veins, IVC) Borders the omental foramen, which connects the greater and lesser sacs Part of lesser omentum
Hepatogastric ligament	Liver to lesser curvature of stomach	Gastric vessels L0	Derivative of ventral mesentery Separates greater and lesser sacs on the right May be cut during surgery to access lesser sac Part of lesser omentum
Gastrocolic ligament	Greater curvature and transverse colon	Gastroepiploic arteries Rt	Derivative of dorsal mesentery Part of greater omentum
Gastrosplenic ligament	Greater curvature and spleen	Short gastrics, left gastroepiploic vessels	Derivative of dorsal mesentery Separates greater and lesser sacs on the left Part of greater omentum
Splenorenal ligament	Spleen to left pararenal space	Splenic artery and vein, tail of pancreas	Derivative of dorsal mesentery

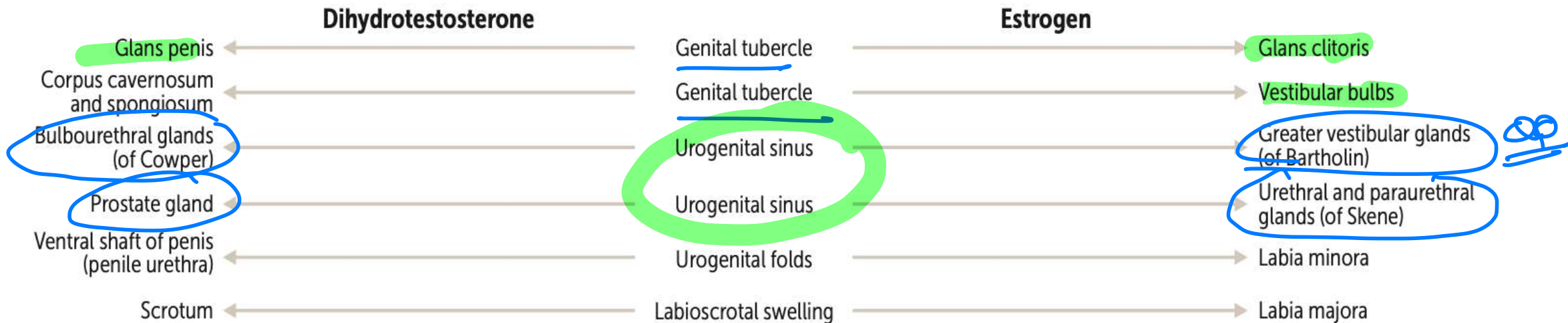


Phrenocolic
+
descent of
spleen
xx



34. Which of the following structures in women is homologous to gubernaculum testis in men?

- A. Round ligament
- B. Broad ligament
- C. Uterosacral ligament
- D. Cardinal ligament



Descent of testes and ovaries

	DESCRIPTION	MALE REMNANT	FEMALE REMNANT
<u>Gubernaculum</u>	Band of fibrous tissue	<u>Anchors testes within scrotum</u>	Ovarian ligament + round ligament of uterus = $R > O$
<u>Processus vaginalis</u>	Evagination of peritoneum	Forms tunica vaginalis <u>Persistent patent processus vaginalis → hydrocele</u>	Obliterated

congenital

44. Which of the following muscles is not involved in the formation of the perineal body?

A. Bulbospongiosus muscle ✓

B. Superficial transverse perineal muscles ✓

C. Deep transverse perineal muscles ✓

D. ~~Internal anal sphincter muscle~~

external anal sphincter

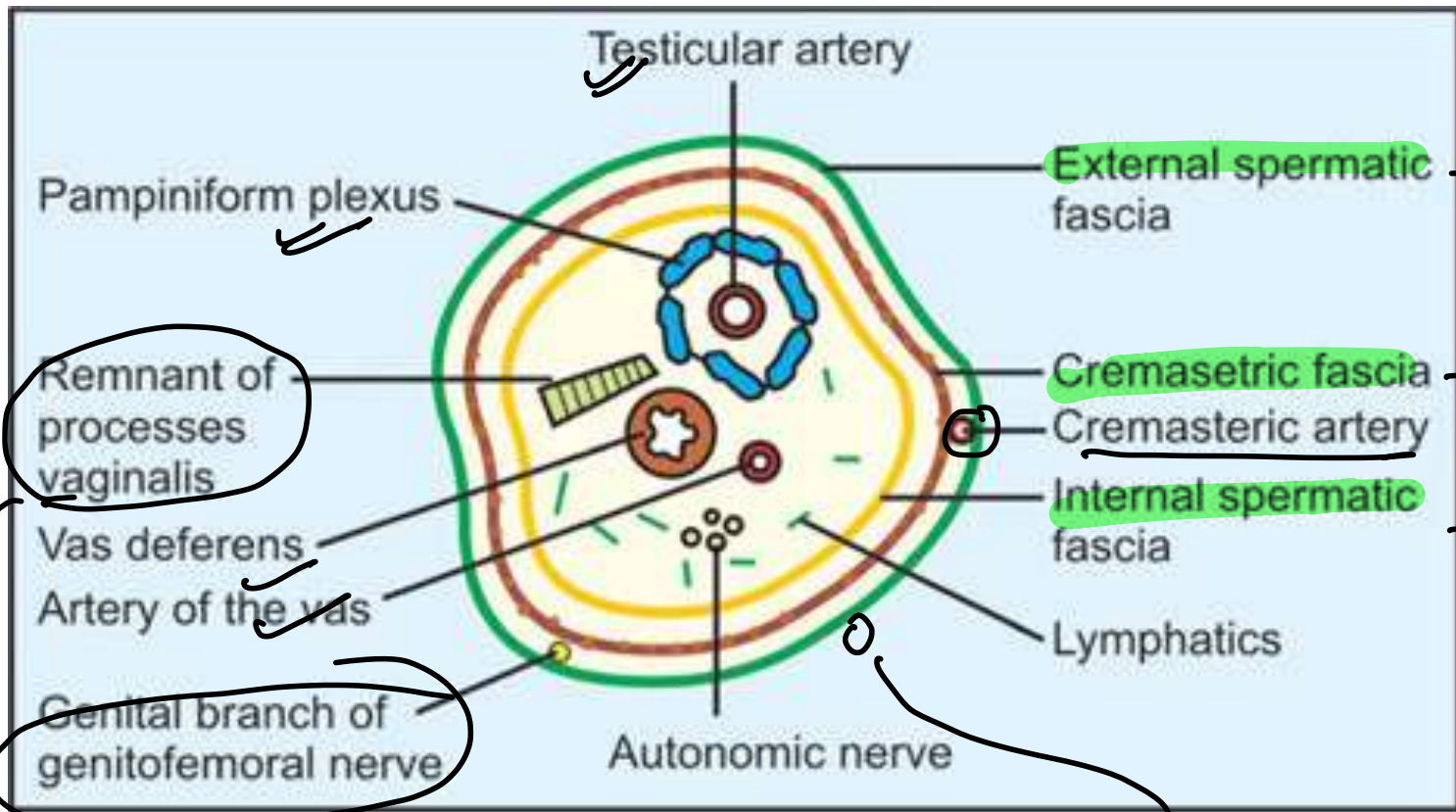
45. Which of the following structures of the inguinal canal lies outside the internal spermatic fascia?

A. Pampiniform plexus of veins

B. Testicular artery ✗

C. Testicular nerve plexus ✗

D. Ilioinguinal nerve



Ext oblique

Int oblique

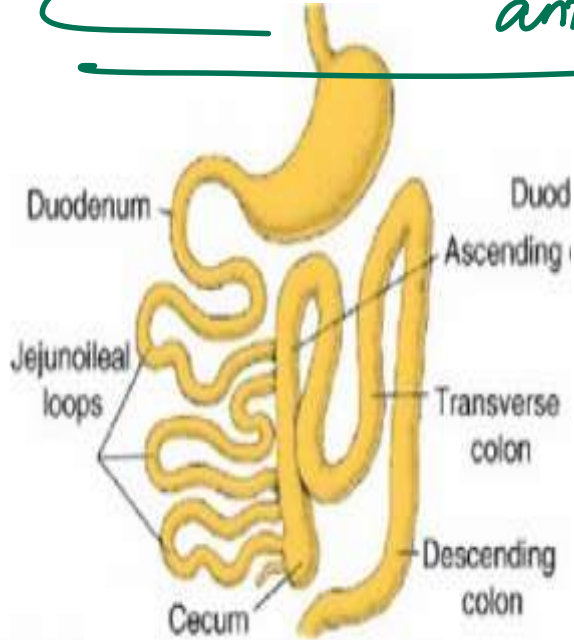
Fascia transversalis

PP

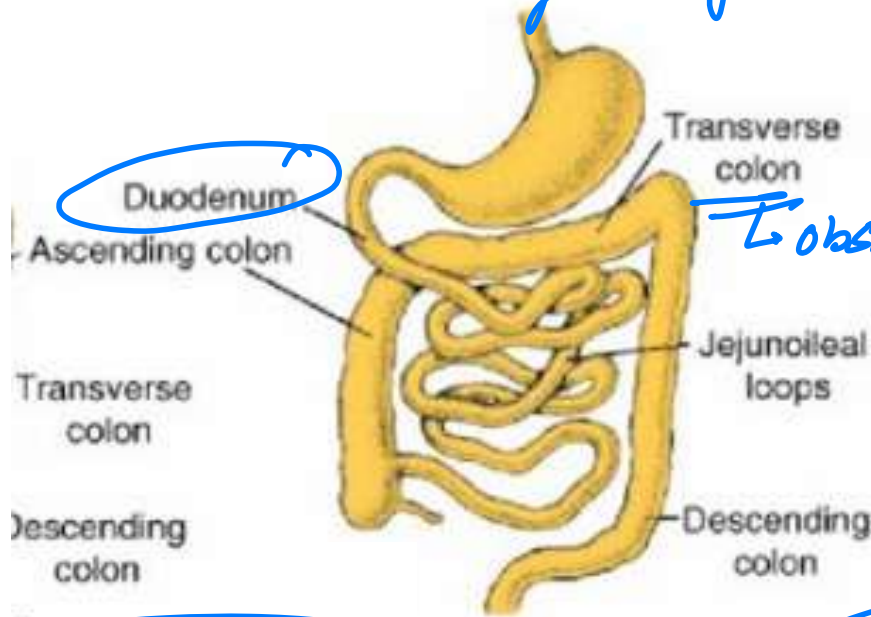
ilioinguinal N - ✓ ing canal
 x sperm cord

ROTATION ABNORMALITIES

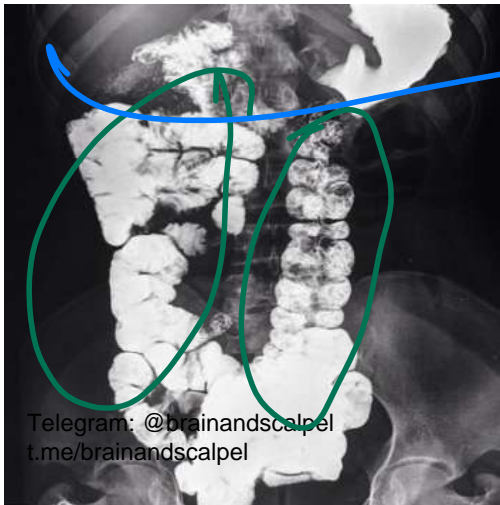
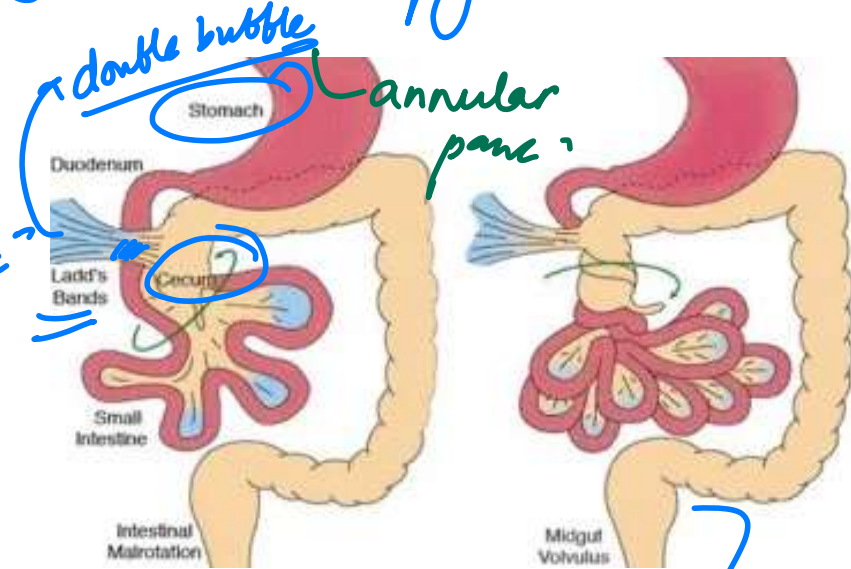
Non rotn - 90° anticlock



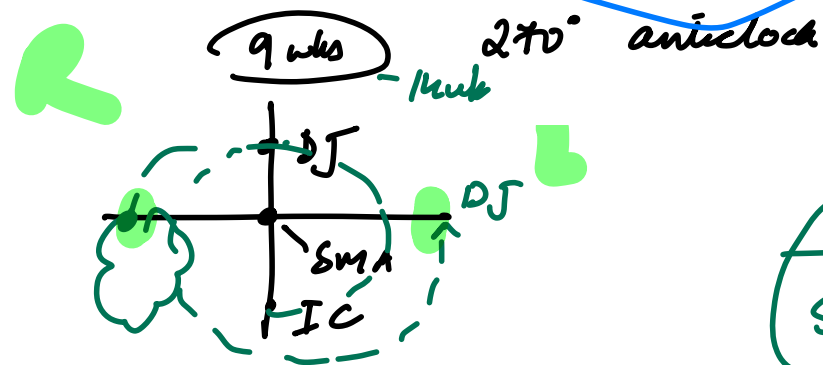
Reverse rotn
Large before small



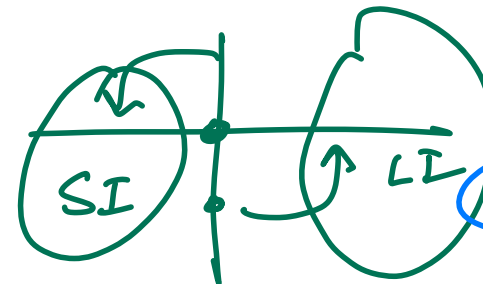
Mixed
subpyloric cecus



Telegram: @brainandscalpel
t.me/brainandscalpel



Midgut
volvulus



Malrotn

31. Which of the following is not an anterior relation of the left ureter while exposing it?

A. ✓ Root of the mesentery

(Rt)

B. Sigmoid mesocolon

C. Left Gonadal vessels

D. Left colic vessels

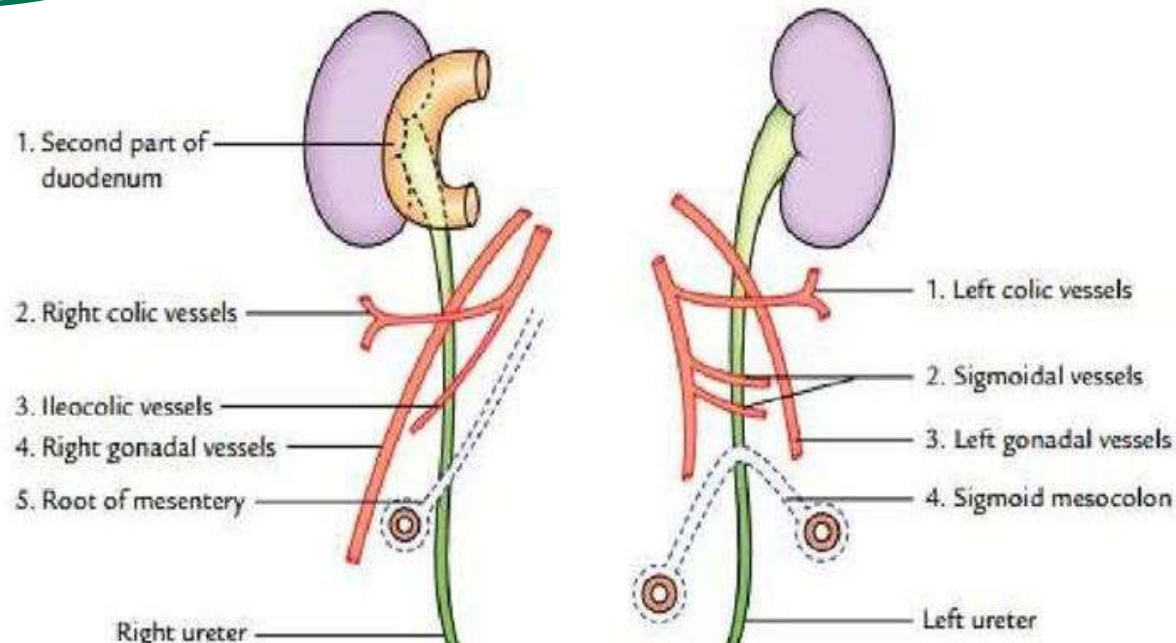
Abdominal part - Anterior Relations

• Right side

- 2nd part of duodenum
- Right colic vessels
- Iliocolic vessels
- Right testicular / ovarian vessels
- Root of mesentery

• Left side

- Left colic vessels
- Sigmoidal vessels
- Left testicular / ovarian vessels
- Sigmoid mesocolon



46. The structure that is present in the deep perineal pouch is?

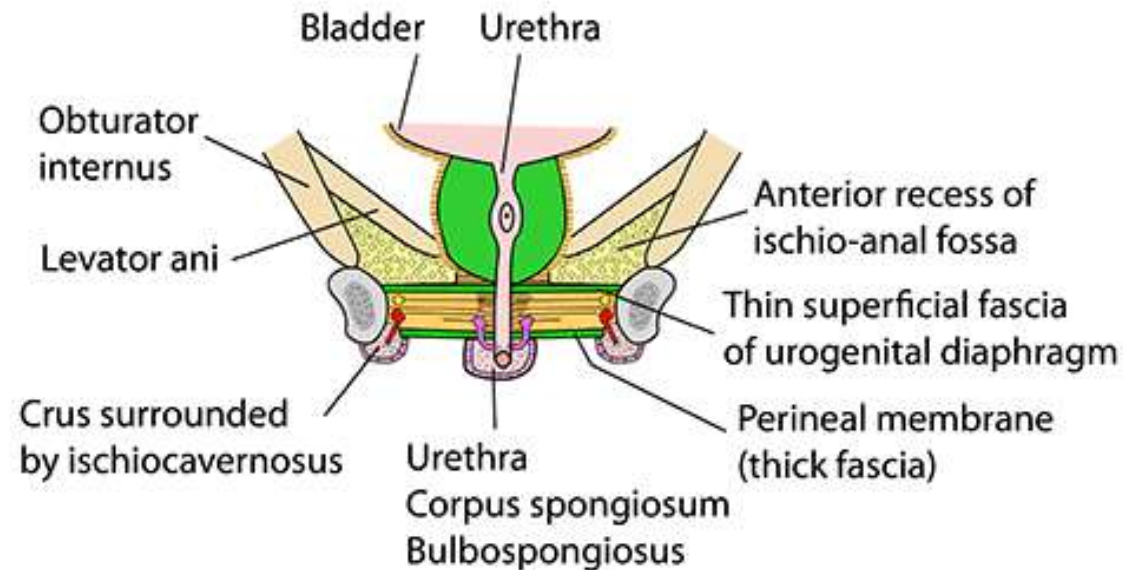
- A. Bulb of the vestibule
- B. Corpus spongiosum
- C. Bartholin glands
- D. Bulbourethral glands



MALE PERINEUM - DEEP PERINEAL POUCH

Deep perineal pouch (between perineal membrane below & superior fascia of urogenital diaphragm above). Contains:

- Membranous urethra
- Deep transverse perinei
- Sphincter urethrae (external sphincter)
- Bulbourethral glands (Cowper's). They drain into urethra below the perineal membrane
- Internal pudendal vessels
- Dorsal nerve of penis $S + D$
- Note that the external sphincter has striated muscle extensions around lower prostatic urethra, above the urogenital diaphragm that are called the **intrinsic urethral mechanism**



Coronal section through urogenital diaphragm at level of the prostate

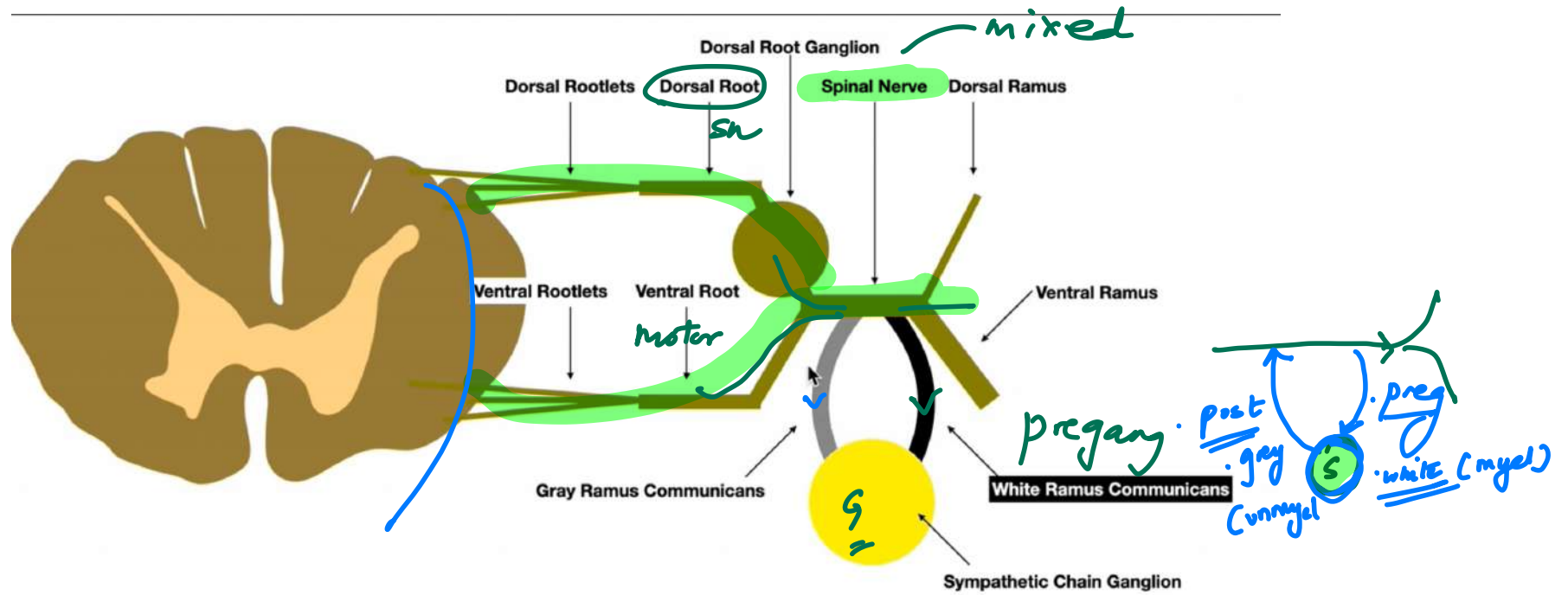
118. All of the following are true about grey rami communicantes except?

A. Unmyelinated

B. Connected to spinal nerve

~~C. Preganglionic~~ *post gang*

D. Present medial to white rami communicantes



25. Which of the following bones violates 'The secondary ossification center that appears first, fuses last' law ?


A. Radius

B. Fibula

C. Ulna

D. Sternum

Primary ossification centres appear before birth and are single



27. Which of the following types of joints is incorrectly matched ?

- A. Acromioclavicular joint – Plane synovial joint
- B. Wrist joint – Condyloid joint
- C. ~~Sternoclavicular joint – Plane joint~~ *saddle*
- D. Intercarpal – Plane synovial joint

Joint Type

Plane (gliding)

Hinge

Pivot

Saddle

Ball and socket

Example

Intercarpal, intertarsal joints

Elbow, interphalangeal joints *ankle*

NO Atlantoaxial joint, Sup-Inferior radioulnar / *Triaxial*

1st carpometacarpal joint (thumb)

Shoulder, hip

Permitted Movements

Gliding movements (limited sliding)

Flexion, extension

Rotation (e.g., pronation/supination)

Flexion, extension, abduction, adduction, circumduction

Flexion, extension, abduction, adduction, rotation, circumduction

Feature	Condylar Joint	Ellipsoid Joint
Articular Surface	Convex rounded condyle fits into a shallow concavity	Elliptical convex surface fits into elliptical concavity
Shape	More cylindrical/rounded	Elliptical (oval)
Degree of rotation	May permit limited axial rotation	No axial rotation
Examples	Knee (femoral condyles on tibia), temporomandibular joint (TMJ), metacarpophalangeal joints (sometimes classified here)	Wrist (radiocarpal joint), metacarpophalangeal joints (MCP)

middle R-U/T-F

syndesmosis

Knee TMJ: cond > ellip

wrist MCP: ellip > cond

35. Which of the following is not a unilayered epithelium?

- A. Simple squamous epithelium
- B. Pseudostratified columnar epithelium
- C. Simple columnar epithelium
- D. Seminiferous epithelium

